

# Other QRS-T Patterns that May Be Mistaken for Myocardial Infarction

## IV. Alterations in Blood Potassium; Myocardial Ischemia; Subepicardial Myocarditis; Distortion Associated with Arrhythmias

BY GORDON B. MYERS, M.D.

The electrocardiograms of patients in whom myocardial infarction was excluded at autopsy are presented to bring out (1) differentiation of patterns due to subendocardial ischemia or hypokalemia from those due to subendocardial infarction; (2) differentiation of cove-plane T inversion associated with subepicardial myocarditis or ischemia from that accompanying myocardial infarction; (3) errors resulting from attempts to draw diagnostic inferences from the registration of prominent Q waves and/or cove negative T waves in ectopic beats or tachycardias.

**T**HE DIFFERENTIATION between the precordial electrocardiogram of myocardial infarction and that associated with left ventricular hypertrophy, right ventricular hypertrophy and dilatation, and bundle branch block has been covered previously.<sup>1-3</sup> In this article, certain electrocardiographic features suggestive of myocardial infarction, but actually referable to alterations of blood potassium, to myocardial ischemia, to subepicardial myocarditis with or without pericarditis, or to QRS distortion associated with arrhythmias are brought out through the presentation of cases in which the possibility of myocardial infarction was excluded at autopsy. The method of study was similar to that described in previous reports.

### ALTERATIONS IN BLOOD POTASSIUM

The electrocardiographic findings associated with both excessive elevation<sup>4-8</sup> and abnormal depression<sup>9-11</sup> of blood potassium have been described fully and need not be reiterated. The possibility of mistaking hypokalemic depression of the RS-T junction and inversion of the T wave for acute subendocardial infarction will be brought out through the presentation of Case 39. The resemblance of certain features of the biphasic QRS-T complex associated with

extreme hyperkalemia to the pattern of extensive infarction with bundle branch block will be brought out through the presentation of Case 40.

*Case 39.*—The patient, a woman, age 45 years, was admitted to the hospital on June 18, 1943, in deep diabetic coma, accompanied by marked dehydration and profound peripheral circulatory collapse. The first electrocardiogram (fig. 1) obtained two hours after admission, when the carbon dioxide combining power was 10 volumes per cent, showed normal QRS complexes and tall, sharply peaked T waves. The latter finding was strongly suggestive of hyperkalemia, but could have been due, in part, to the acidosis. During the first twenty-four hours, the patient received 1540 units of insulin, 1000 cc. of plasma, and 14,000 cc. of parenteral fluid, partly in the form of physiologic saline, partly as 5 per cent glucose. Peripheral circulatory collapse persisted until June 19 and normal blood pressures were maintained thereafter. No cardiac glycosides were given at any time to this patient.

The second tracing was obtained shortly after recovery from shock, when the carbon dioxide combining power was 50 volumes per cent and blood sugar 450 mg. per 100 cc. of blood. The QRS deflections showed slight reduction in voltage, but no significant change in configuration. On the other hand, striking changes occurred in the RS-T complexes, characterized by a 1-mm. depression of the RS-T segments and flattening of the T waves in Leads I and II; a reversal in the direction of T<sub>3</sub>; a 2-mm. depression of the RS-T segments and inversion of the previously tall erect T waves in Leads V<sub>4</sub> and V<sub>6</sub>; an apparent lengthening of the Q-T interval in Leads V<sub>1</sub> and V<sub>6</sub>. These changes were attributed to acute ischemia or patchy infarction.

From the Department of Medicine, Wayne University, and City of Detroit Receiving Hospital, Detroit, Mich.

tion of the subendocardial aspect of the anterolateral wall of the left ventricle, consequent upon the prolonged shock. The possibility of hypopotassemia was not considered at the time, but appears likely, in view of the recent reports of Holler<sup>12</sup> and of Martin and Wortman.<sup>13</sup> The severe dehydration antedating admission should have been accompanied by shift of potassium from cells to plasma, and should have resulted in elevation of blood potassium and marked loss in the urine. The excessive fluid intake during the first twenty-four hours should

as shown by the appearance of edema and alkalosis. Repeat tracings on June 21 and 23 showed no significant change in QRS contour, but the voltage was reduced in Leads II, III, and V<sub>4</sub>, probably owing to edema. The depressed RS-T segments progressively approached the isoelectric line and the inverted T waves became upright in Lead V<sub>4</sub> and isoelectric in V<sub>6</sub>. The improvement in RS-T complex and T wave occurred despite the deterring influence of alkalosis,<sup>14</sup> as evidenced by a carbon dioxide combining power maintained at 80 volumes per

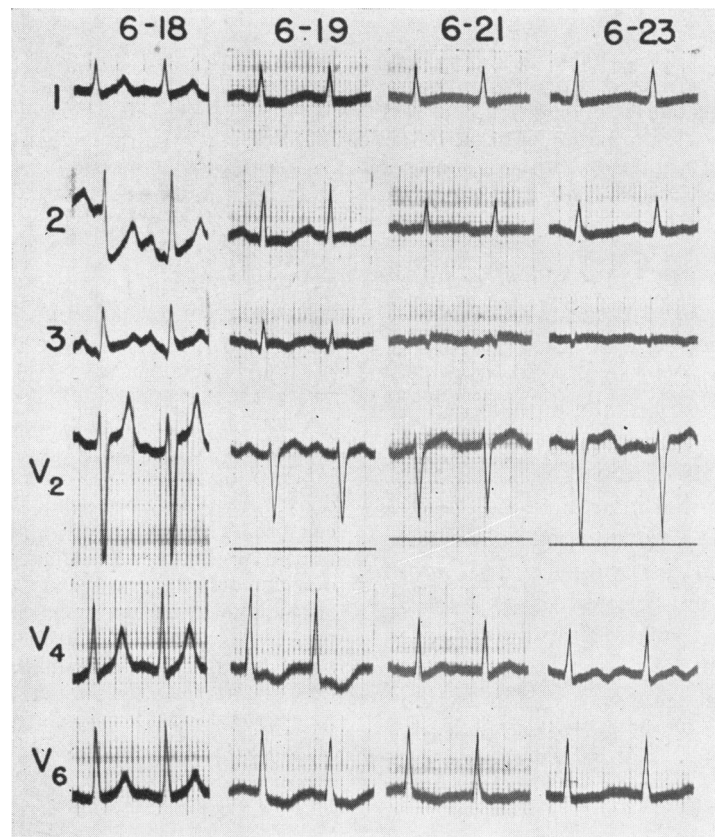


FIG. 1.—Serial electrocardiograms in Case 39.

have caused further loss of potassium in the urine and the restoration of carbohydrate metabolism under the stimulus of large doses of insulin should have caused shift of potassium from plasma to liver, thereby reducing blood potassium to dangerously low levels.

The blood sugar reached normal levels on June 20, as a result of an additional 800 units of insulin during the second twenty-four-hour period and was maintained between 100 and 200 mg. per 100 cc. of blood thereafter by an average dose of 75 units of insulin daily. An additional 5000 cc. saline and glucose solution given on June 19 proved excessive,

cent, and was probably due to partial replenishment of potassium by oral feedings.

Deep coma was replaced by stupor on June 19 and by drowsiness on June 20, but complete mental clearing failed to occur. After a four-day interval of drowsiness and irrationality, the patient lapsed into coma and died on June 25. The diabetes was under good control and moderate alkalosis was still present at the time of death. The principal autopsy finding was subcortical devastation necrosis, attributed to cerebral anoxia. The heart weighed 350 grams. The coronary vessels were normal by injection and dissection and no evidence of myo-

cardial infarction was found. The serial changes in the electrocardiogram were, in retrospect, probably the result of alterations of blood potassium.

*Case 40.*—The patient was a man, 37 years of age, who gave a history of diabetes mellitus of thirteen years' duration, intermittent dependent edema for five years, hypertension for two years, exertional dyspnea for one year, and blurring of vision for five months. Examination revealed hypertensive neuroretinopathy Grade 4, peripheral edema, albuminuria, and azotemia. The electrocardiogram of February 27, made shortly after admission and reproduced in figure 2, showed tall R waves and deeply inverted T waves in Leads  $V_5$  and  $V_6$  referable to left ventricular hypertrophy.

The hospital course was marked by a gradually increasing renal insufficiency up until the morning

elevated RS-T junction and covelike RS-T segment and T wave associated with recent myocardial infarction. However, from measurements of the QRS interval in other leads, it was evident that the RS-T junction was not at the right-angle bend, but rather at the notch in the lowermost point of the complex. Thus, the plateau following the right-angle bend and the subsequent descent were a part of the prolonged QRS and referable to the conduction defect of hyperpotassemia and were not a sign of infarction.

Death occurred seven hours after the last tracing. At autopsy the heart weighed 426 grams and showed slight left ventricular hypertrophy, but no evidence of infarction. The coronary vessels were of normal caliber and showed only minimal sclerosis. Renal sections showed far advanced intercapillary glo-

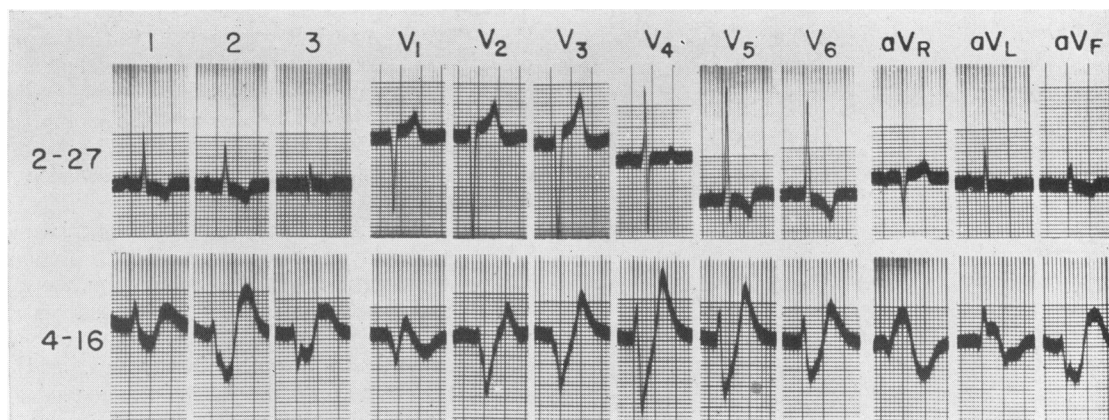


FIG. 2.—Serial electrocardiograms in Case 40.

of April 16, when the patient awoke with generalized flaccid paralysis, profound circulatory collapse, and anuria. Electrocardiogram revealed auricular standstill, a QRS interval of 0.24 second, marked widening of the terminal portion of the QRS, and sharp peaking of the T wave typical of extreme hyperpotassemia. A distinct initial R wave was recorded in Leads  $V_1$ ,  $V_2$  and  $V_4$ , but a QS complex was present in  $V_3$ . This finding was considered analogous to the reduction or disappearance of the initial R wave sometimes found in leads at the transitional zone in uncomplicated bundle branch block<sup>3</sup> and hence did not constitute evidence of infarction.

The feature of hyperpotassemia that led to the inclusion of this case was the fusion of the terminal portion of the QRS with the T wave to make a pattern resembling that of infarction. This was best exemplified by Lead  $aV_L$  of the tracing of April 16. After the inscription of a small Q wave, a slightly prolonged upstroke and the first half of a precipitous intrinsicoid downstroke, the string veered at a right angle and then moved downwards in an arc, which at first glance resembled the

merulosclerosis of the type described by Kimmelsiel and Wilson.

#### ACUTE MYOCARDIAL ISCHEMIA

During acute myocardial ischemia, leads facing the epicardial surface of the involved area may show transitory depression of the RS-T segment and/or inversion of the T wave, usually without change in the QRS complex.<sup>15-19</sup> When the acute ischemia is confined to a portion of the circumference of the left ventricle, leads facing the opposite, uninvolved wall may display reciprocal elevation of the RS-T segment and/or tall erect T waves.<sup>20,21</sup>

Acute RS-T depression of similar magnitude and configuration may be observed in association with infarction or ischemia confined to the subendocardial layer of myocardium. Acute subendocardial ischemia may occur in previ-



ously normal hearts as a result of shock secondary to perforated peptic ulcer, hemorrhagic pancreatitis, intestinal obstruction, and other surgical conditions. When confronted with a

of RS-T segments and exaggeration of T waves in leads from the opposite wall, does not establish the former nor exclude the latter alternative.<sup>22-24</sup>

The problem in differential diagnosis between acute subendocardial infarction and an acute surgical abdomen complicated by myocardial ischemia and the error that may result from overemphasis of electrocardiographic findings is exemplified by Case 41.

*Case 41.*—The patient was a 69 year old woman, who had had hypertension for several years, but was otherwise in good health until July 20, 1948, when she was awakened by severe epigastric pain, radiating retrosternally. The pain remained constant and no new symptoms appeared during the next three days. The patient was brought to the hospital on July 23 in shock with unobtainable blood pressure and cold, clammy extremities. The heart was not enlarged, and showed a mesodiastolic gallop and a rate of 130 with frequent premature beats. The abdomen was slightly distended, but revealed no tenderness, rigidity, or masses.

The first electrocardiogram (fig. 3) obtained on admission displayed sinus tachycardia with frequent auricular premature systoles, followed by aberrant ventricular response and rarely by dropped ventricular beat. The QRS complex of the sinus beats was not remarkable in contour in any lead, but that of the auricular premature beats in Leads aV<sub>F</sub>, II and III was characterized by an equiphasic QR complex. These QR complexes conformed with the pattern of posterior infarction, as shown by a 0.03-second interval from onset to nadir of the Q wave in aV<sub>F</sub> and a QR ratio of 100 per cent. This finding, together with the apparent 4-mm. RS-T depression in the cycles of sinus origin in Lead aV<sub>F</sub>, led the resident to make a diagnosis of recent infarction of the subendocardial portion of the posterior wall, whereas the 1- to 2-mm. RS-T depression in Leads V<sub>4</sub>, V<sub>5</sub> and V<sub>6</sub> was ascribed to continuation of the infarct into the subendocardial aspect of the anterolateral wall. The marked increase in RS-T depression in Leads V<sub>4</sub> and V<sub>5</sub> during the next three hours was interpreted by the resident as evidence confirming his impression of extension of the infarct into the subendocardial portion of the anterolateral wall, and the changes on the following day did not induce him to alter his diagnosis. The patient remained in shock and blood pressure was unobtainable except for brief periods after plasma transfusions. A terminal tracing at 1:00 p. m. on July 24 showed complete A-V block and death by ventricular standstill.

The tracings were studied by the author after death of the patient, but prior to knowledge of the autopsy, and a different interpretation was placed

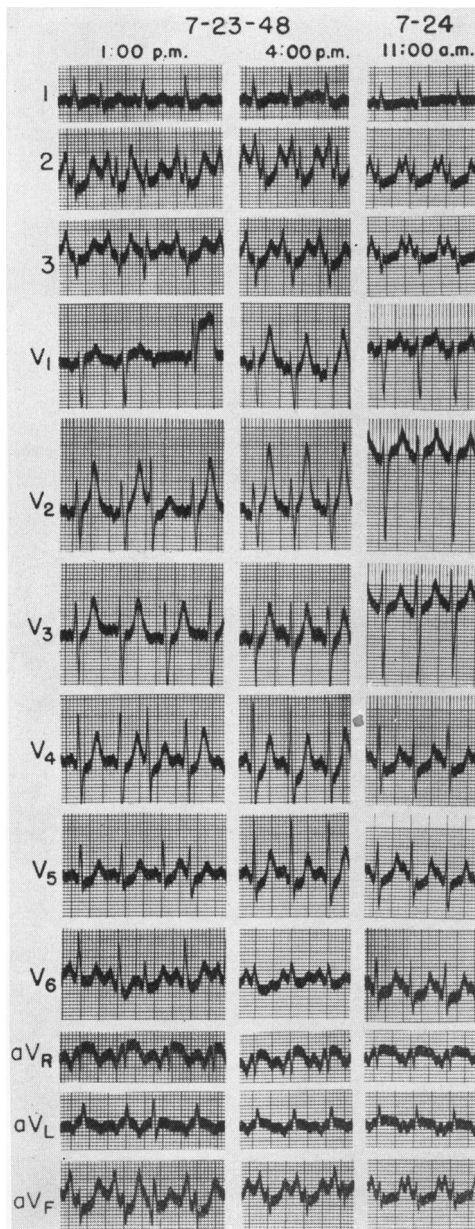


FIG. 3.—Serial electrocardiograms in Case 41.

clinical picture that raises the differential diagnosis between acute myocardial infarction and an acute surgical abdomen, the demonstration of abnormal RS-T depression and/or T-wave inversion, with or without reciprocal elevation

upon the findings. Inasmuch as RS deflections were registered in all cycles of sinus origin in Leads  $aV_F$ , II, and III, the abnormal QR deflections associated with ectopic auricular beats were not considered diagnostic of posterior infarction, since they could be explained by aberrant intraventricular conduction of the premature impulse, to be discussed later. The 4-mm. depression of the RS-T junction in  $aV_F$  was considered more apparent than real because of the tachycardia and the high voltage of the auricular complex. The heart was sufficiently rapid so that the beginning of the P wave was engrafted upon the end of the preceding T wave, thereby preventing return of the string to the isoelectric level. The extremely tall P wave in Lead  $aV_F$  was followed by an exceptionally deep  $T_a$  wave. The beginning of the  $T_a$  wave could be seen in front of the R wave and the remainder of the  $T_a$  wave could largely, if not entirely, account for the low level of the string following the S wave. Hence, the low level of the RS-T segment was regarded as a pseudodepression of no diagnostic significance.

The question arose as to whether the RS-T depression in the last three precordial leads could be explained entirely by tachycardia and the  $T_a$  deflection or whether it was due in part to a lesion in the subendocardial layer of the anterolateral wall. This question was settled by the marked increase in RS-T depression in  $V_4$  and  $V_5$  three hours later with little change in rate or P waves. The increasing RS-T depression in  $V_4$  and  $V_5$  was, therefore, indicative of a lesion of the subendocardial layer of the anterolateral wall of the left ventricle. The findings were attributed to acute ischemia, rather than to subendocardial infarction, because of an increase, rather than a decrease, in the amplitude of the initial R waves in Leads  $V_4$  and  $V_5$ . The elevated RS-T junction and terminal inversion of the T wave in Lead  $aV_R$  were the result of cavity potentials reciprocal to those responsible for the findings in Lead  $V_6$ . The high-peaked T waves in Leads  $V_1$  and  $V_2$  aroused the suspicion of hyperpotassemia and the progressive narrowing of the base and sharpening of the apex of the T wave in the last two tracings, along with the lengthening of the Q-T interval, were best explained on this basis. Thus, the electrocardiographic findings were attributed in part to acute ischemia of the subendocardial portion of the anterolateral wall of the left ventricle and in part to hyperpotassemia. Unfortunately the blood potassium was not determined.

Autopsy revealed gangrene of the ileum as the cause of death and showed no evidence of myocardial infarction or coronary narrowing. The heart weighed only 200 grams. There was pallor of the subendocardial two-thirds of the left ventricular wall on gross examination and subendocardial interfibrillary edema without alteration of nuclei or striations was found on microscopic study of a number of blocks. These findings were attributed to myocardial is-

chemia and thus gave support to the revised interpretation of the electrocardiographic findings.

Cove-plane T waves, manifested by upward bowing of the RS-T segment, sharp inversion of the T wave, and a progressive evolution in serial tracings, are not pathognomonic of myocardial infarction, but may be found in association with acute myocardial ischemia,<sup>25, 26</sup> pericarditis,<sup>27, 28</sup> and other conditions.<sup>1, 2, 3</sup> The association of cove-plane T waves with acute myocardial ischemia is exemplified by Cases 42 and 43 and the association with pericarditis by Cases 44 and 45.

*Case 42.*—The patient was a janitor, 58 years of age, who had had intermittent epigastric pain, radiating into both sides of the chest, and increasing exertional dyspnea for a period of six months. There were physical signs of syphilitic aortic insufficiency, aneurysm of the ascending aorta, and hypersensitivity of the carotid sinus. No cardiac glycosides were given.

Electrocardiograms obtained on May 9, shortly after admission to the hospital, and repeated after a week of hospitalization, are reproduced in figure 4. The striking findings in the first tracing were the sharply inverted T waves and convex RS-T segments in the last five precordial leads, associated with isoelectric RS-T junctions and normal QRS complexes. The RS-T pattern in these leads was compatible with anterolateral infarction, myocardial ischemia, or pericarditis. The normal QRS complexes were strongly against the classical variety of anterolateral apical infarct, but were consistent with (1) the very rare infarct limited to the subepicardial layer of the apical portion of the anterolateral wall; (2) an ischemic zone beyond the border of an infarct localized to the basal portion of the anterolateral wall. High precordial leads should have been taken to investigate further this latter possibility.

The tracing of May 16 showed increase in R wave at the expense of the S in  $aV_L$  and in the last four precordial leads, probably due chiefly, if not entirely, to counterclockwise rotation. The QRS deflection was still considered within the limits of normal. A much greater change occurred in the RS-T segment and T wave in the last five precordial leads and could not be explained by the cardiac rotation. The previously inverted T waves had become low upright in the last five precordial leads, whereas the previously isoelectric RS-T junctions became considerably depressed in  $V_4$  and slightly depressed in  $V_3$  and  $V_5$ . The development of RS-T depression was strongly against pericarditis or subepicardial infarction, but consistent with ischemia of the apical portion of the anterior wall. High precordial leads



should also have been taken on this date to rule out the possibility that the apical ischemic zone was associated with an infarct localized in the base of the anterolateral wall.

Death occurred three weeks later. At autopsy the heart weighed only 393 grams. Syphilitic aortic insufficiency, aneurysm of the ascending aorta, and narrowing of the coronary ostia were found. The epicardium was normal and no evidence of infarction was found on gross examination or in the twelve microscopic blocks studied. However, a patchy fibrosis was found in the majority of these blocks and was believed secondary to coronary insufficiency. Thus, autopsy excluded the possibility of myocardial infarction and pericarditis, but revealed changes which suggested that myocardial ischemia was responsible for the electrocardiographic abnormalities.<sup>29</sup>

*Case 43.*—The patient was a 15 year old school girl, who gave a history of recurrent episodes of anemia since the age of six. She was admitted to the hospital in a severe relapse. The anemia was

position  $V_4$  and was subsequently excluded by the disappearance of the inversion.

With the aid of transfusions, a progressive rise in red blood and hemoglobin occurred during November, to reach levels of 3,650,000 per cu. mm. and 62 per cent, respectively, on December 2. Parallel changes in T waves occurred, characterized by progressive increase in amplitude in Leads  $V_6$ , I and II, by metamorphosis of the deeply inverted T wave in  $V_4$  to a normal upright deflection, and by change from a deeply inverted to diphasic to flattened T wave in  $V_2$ . No significant alteration occurred in the normal QRS complexes. Because of the parallelism between improvement in T waves and blood count, it was concluded that the initial cove-plane inversion was most likely an expression of acute myocardial ischemia secondary to the hemolytic crisis.<sup>30</sup> The possibility of acute cor pulmonale was given serious consideration in the differential diagnosis, but was deemed less likely because of the deeper inversion of the T waves in Lead

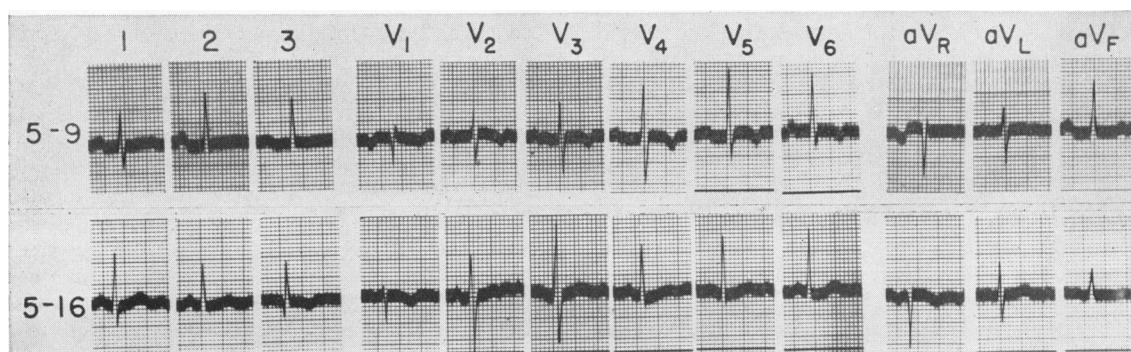


FIG. 4.—Serial electrocardiograms in Case 42.

established as hemolytic in type by fecal stercobilin excretion ranging from 720 to 1042 mg. in twenty-four hours. Sarcoidosis was discovered on bone marrow examination and was confirmed by lymph glandular biopsy. No cardiac glycosides were given.

The electrocardiogram of Oct. 31, 1944 (fig. 5), was obtained during the severe relapse, when the red blood count was 1,050,000 per cu. mm. of blood and the hemoglobin was 20 per cent. The QRS complexes were normal in all leads. The RS-T junctions were isoelectric throughout. The T waves were flattened in Leads  $V_6$  and I. The striking feature was the sharp inversion of the T waves in Leads  $V_2$  and  $V_4$ . Although the RS-T segments and T waves in these leads mimicked the cove-plane pattern of myocardial infarction, no consideration was given to such a diagnosis in the clinical interpretation because of the normal QRS complexes and the age of the patient. The possibility that the inverted T waves represented a normal variant of adolescence was deemed unlikely because of the depth of the T waves in a lead as far to the left as

$V_4$  than in  $V_2$ . An intercurrent pericarditis was a further alternative that could not be excluded by electrocardiographic findings.

Splenectomy was performed on December 5, but death occurred four weeks later in another hemolytic crisis. The diagnosis of sarcoidosis was confirmed at autopsy. The heart and coronary arteries were entirely normal to gross and microscopic examination. The negative pathologic findings constituted indirect evidence supporting the antemortem ascription of the transiently inverted T waves to acute myocardial ischemia secondary to acute hemolytic anemia.

#### PERICARDITIS AND SUBEPICARDIAL MYOCARDITIS

Although the RS-T pattern associated with pericarditis was described in 1929<sup>31, 32</sup> and repeatedly elaborated upon during the next decade,<sup>33-37</sup> reports continue to appear of cases with

electrocardiograms typical of pericarditis, in which the authors made a diagnosis of "coronary occlusion" or myocardial infarction and failed to mention the possibility of pericarditis.<sup>38-40</sup> This indicates the need for a brief resume of the electrocardiographic findings in pericarditis and re-emphasis of the features that

carditis. During the acute stage, the RS-T junction is characteristically elevated and is followed by a monophasic upright T wave. At first, the RS-T segment usually ascends in a straight line or in a curved line with upward concavity, but may exhibit an upward convexity similar to that in myocardial infarction.

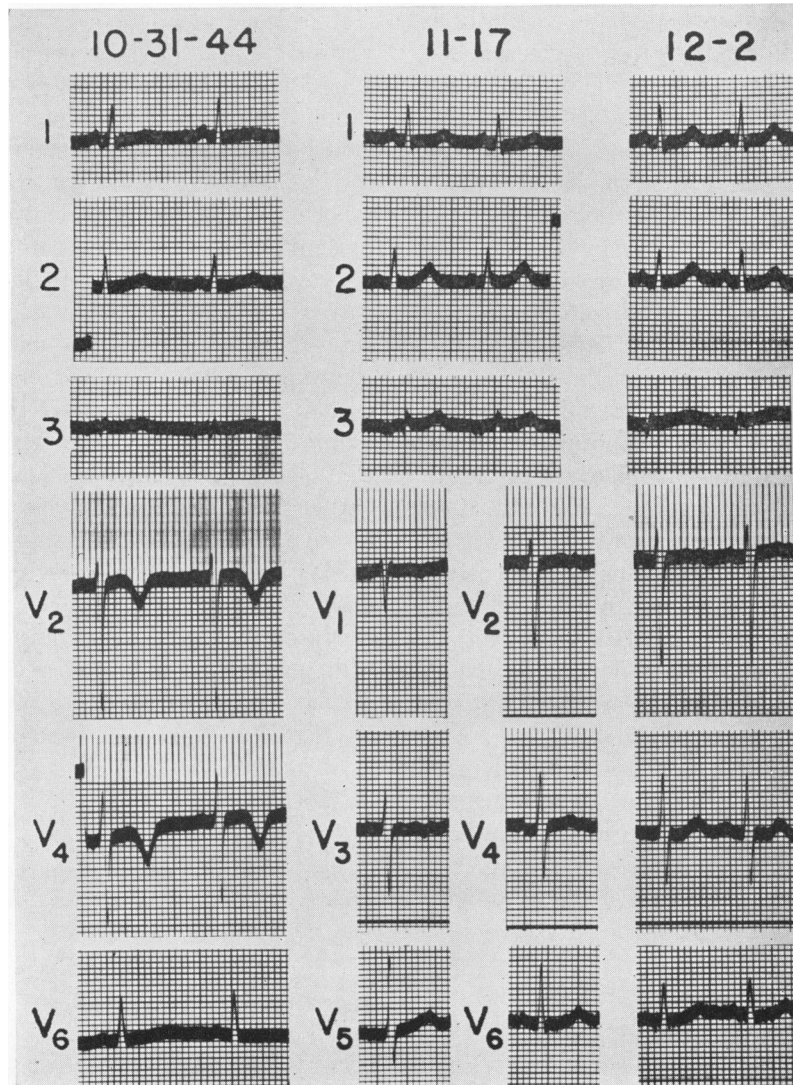


FIG. 5.—Serial electrocardiograms in Case 43.

may be mistaken for those of myocardial infarction.

The RS-T changes about to be described are an expression of a lesion of the superficial layers of myocardium,<sup>33-37,41</sup> rather than an involvement of the epicardium per se, but, through custom, are designated as the pattern of peri-

As the acute passes into the subacute stage, serial tracings reveal a progressive return of the RS-T junction to the isoelectric line, accompanied by a change to an upwardly convex, domelike RS-T segment, and a deepening coveplane inversion of the T wave, similar to that in myocardial infarction. As the lesion heals,



there is a progressive return to normal upright T waves.

The RS-T and T pattern of pericarditis, both in individual and in serial tracings, may be identical with that accompanying acute myocardial infarction. Certain minor differences in the distribution of the abnormal T waves and in their rate of evolution may aid in the electrocardiographic differentiation of pericarditis and myocardial infarction. In the former, comparable RS-T patterns are usually found in leads facing the anterior and posterior ventricular surface, owing to the tendency towards generalization of pericarditis; in the latter, reciprocal RS-T patterns are characteristically present owing to the tendency for localization of infarction to one wall. The evolution of the RS-T changes is usually much more rapid in pericarditis than in myocardial infarction.

The most important criterion in differential diagnosis is the direction of the initial deflection of the QRS wave. An abnormal Q wave is usually demonstrable in an overlying lead within a few hours after infarction of the subjacent wall, persists throughout organization of the lesion, and often remains permanently. On the other hand, Q waves are not produced by pericarditis or subepicardial myocarditis; however, a pre-existent Q wave may persist after the development of pericarditis and may give rise to diagnostic difficulties. In pericarditis, the R wave may be reduced in voltage, but remains normal in contour; in myocardial infarction, abnormal reduction in the R wave is characteristically present in leads facing the lesion and is often accompanied by abnormal slurring, notching or widening of the QRS complex.

In spite of the foregoing criteria, pericarditis and myocardial infarction may be confused electrocardiographically. Diagnostic difficulties may be encountered in the presence of the following three patterns: (1) Localized abnormal elevation of the RS-T junction and/or cove-plane inversion of the T wave in the presence of an initial R wave of normal or low voltage. Such a pattern is characteristic of a lesion of the subepicardial layer of myocardium and is usually not infarctive in origin. Before reaching a diagnosis of pericarditis, however, it is neces-

sary to consider the rare infarct limited to the subepicardial layer and the less rare situation in which there is a widespread pericardial reaction secondary to a relatively small infarct localized to a portion of the wall not subtended by the customary precordial and limb leads. To further investigate the latter, supplementary leads should be obtained from the V<sub>7</sub> and V<sub>8</sub> positions and from the upper precordium and left axilla at the horizontal level of the junction of third intercostal space and sternum. (2) Abnormal elevation of the RS-T junction and/or cove-plane inversion of the T wave, in complexes exhibiting a distinct Q wave and a normal to borderline Q/R ratio. This combination brings up the differentiation between pericarditis in a person with pre-existent Q waves and infarction involving a thin layer of subendocardial muscle and extending through the wall in patchy fashion to reach the subepicardial layer. (3) Localized reduction in the amplitude of the R wave in a given lead below that attained in adjacent leads to the right and left. Such a finding suggests of patchy infarction, but may be associated with pericardial thickening or effusion. Four cases of pericarditis (Cases 44 to 47, inclusive), that collectively exemplify the foregoing three patterns, will be presented to bring out the features that may be mistaken for those of myocardial infarction.

*Case 44.*—The patient was a girl 19 years of age. She was admitted to the hospital on May 15 with a history of transitory sore throat three weeks previously and migratory joint pain and swelling of one week's duration. A pericardial friction rub was audible during the first week in the hospital, but no evidence of pericardial effusion was detected at any time. Embolic phenomena were first observed on June 3, signs of aortic insufficiency were detected on June 8, and congestive failure developed on June 13. No cardiac glycosides were given until June 14, when 0.8 mg. Cedilanid was injected intravenously one hour prior to the tracing.

Serial electrocardiograms are reproduced in fig. 6A. The tracing of May 15 showed elevated dome-like RS-T segments and sharply inverted T waves in the last four precordial leads and in all three limb leads, simulating the cove-plane contour of recent myocardial infarction. However, the normal initial R waves in each of these leads indicated that the lesion was probably confined to the sub-



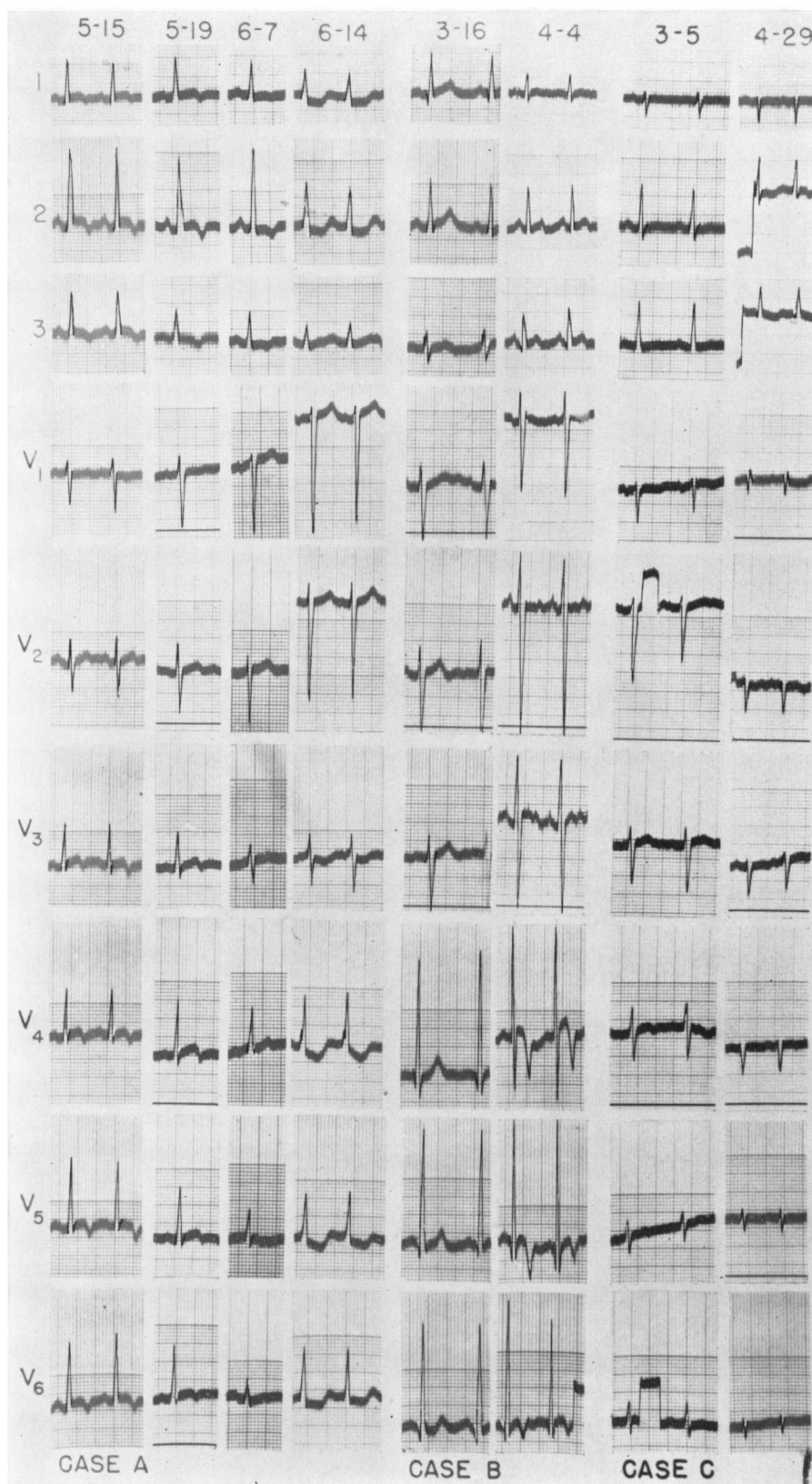


FIG. 6.—Serial electrocardiograms in pericarditis and subepicardial myocarditis.  
A, Case 44; B, Case 45; C, Case 46.

epicardial layer and thus were strongly in favor of pericarditis and against myocardial infarction. To exclude more definitely the possibility of localized high anterior, high lateral or posterior infarction, additional leads are usually advisable from the back, upper precordium and axilla. Such a procedure was unnecessary in this case, in view of the clinical picture.

The last four precordial leads on May 19 showed pronounced domelike RS-T elevation and a sharp, though shallow, inversion of the terminal portion of the T waves. This RS-T pattern simulated that associated with recent myocardial infarction, but could also be ascribed to a superficial lesion because of the normal initial R waves. The regression in RS-T abnormalities and reduction in the voltage of the R waves in the tracing of June 7 were consistent with the evolution in pericarditis. On the other hand, the marked RS-T depression and the slurring and prolongation of the ascending limb of the R waves, which appeared in Leads V<sub>4</sub>, V<sub>5</sub>, V<sub>6</sub>, I and II on June 14, were not attributable to pericarditis. The contour of the RS-T segments was suggestive of digitalis action, but the degree of depression was much greater than is customarily observed after doses of 0.8 mg. Cedilanid. Furthermore, the fact that the Q-T interval was beyond the upper limits of normal and relatively longer than in previous tracings indicated that Cedilanid was not the major factor in the RS-T changes. From the combination of slurring and prolongation of the ascending limb of the R waves with RS-T depression and Q-T lengthening, it was postulated that the subepicardial myocarditis had extended through in patchy fashion to the subendocardial layer.

Death occurred three hours after the last tracing. At autopsy the heart weighed 390 grams and showed evidence of a diffuse fibrinous pericarditis, without effusion, and an acute vegetative aortic valvulitis, superimposed on acute rheumatic endocarditis. The epicardial inflammatory reaction had extended into the superficial layer of myocardium. In addition, there was an acute rheumatic myocarditis distributed in patchy fashion through the deeper layers of myocardium. This was believed to have been the major factor in the terminal changes in the R waves and RS-T complexes in left precordial leads.

*Case 45.*—The patient was a laborer, 30 years of age, who gave a history of rheumatic fever complicated by a valvular lesion in 1939. He was admitted to the hospital on March 16, 1946, because of sudden hemiplegia. Examination revealed left ventricular hypertrophy, aortic insufficiency, embolic phenomena and positive blood cultures for *Streptococcus viridans*.

The tracing taken shortly after admission on March 16 is reproduced in figure 6B along with a repeat electrocardiogram obtained on April 4. The last three precordial leads on March 16 displayed

Q waves averaging 3 mm. in depth, R waves ranging from 28 to 32 mm. in height, upwardly concave RS-T segments, and normal erect T waves. Since the time interval from onset to nadir of the Q waves did not exceed 0.02 second and since the Q/R ratio was in the neighborhood of 10 per cent, it was concluded that the Q waves were normal. The possibility of left ventricular hypertrophy was suggested by the high voltage of the R waves, but a diagnosis of such could not be made electrocardiographically, in view of the normal duration of the ascending limb of the R wave and normal contour of RS-T segments and T waves.

The patient failed to respond to large doses of penicillin. Acute pulmonary congestion developed on April 2, necessitating rapid digitalization. Unfortunately, a repeat electrocardiogram was not obtained until April 4. Leads V<sub>4</sub> and V<sub>5</sub> showed very striking changes from upwardly concave to convex, domelike RS-T segments, and from normal erect T waves to deeply and precipitously inverted, narrow-based T waves. In Lead V<sub>6</sub>, a less deep, cove-plane inversion took place. The possibility of overdigitalization was considered because of the short Q-T interval and the demonstration of cove-plane inversion of the T waves after toxic doses of digitalis in animals,<sup>12</sup> but was discarded because of the normal P-R interval and the lack of typical digitalis effects in other leads. The T wave pattern in V<sub>4</sub> and V<sub>5</sub> was the reciprocal of that associated with hyperpotassemia, but the lack of typical changes in other leads excluded such a possibility. The fact that the deep T-wave inversion was confined to Leads V<sub>4</sub>, V<sub>5</sub> and V<sub>6</sub> pointed to a localized lesion in the anterolateral aspect of the left ventricle. The presence of Q waves 3 mm. deep in V<sub>6</sub> and 3 to 5 mm. deep in V<sub>5</sub> might have led to a diagnosis of recent anterolateral infarction, were it not for the extremely tall succeeding R waves on April 4 and the presence of a comparable QR pattern in the previous electrocardiogram. The fact that the time interval from onset to nadir did not exceed 0.02 second, coupled with the QR ratios below 15 per cent in the tracing of April 4, indicated that the Q waves were comparable to those in the previous tracing and were not attributable to infarction. As a consequence, a diagnosis of localized pericarditis was made.

Death occurred on April 7. Autopsy revealed subacute vegetative aortic valvulitis and widespread miliary abscesses of embolic origin. The heart weighed 521 grams and showed evidence of left ventricular hypertrophy. The coronary arteries were normal. There was no evidence of myocardial infarction and no gross signs of pericarditis. However, microscopic examination revealed an acute subepicardial myocarditis, which was believed responsible for the RS-T changes.

*Case 46.*—The patient, a Negro man, 23 years of age, was hospitalized from February 22 to May



14 with a plateau fever, averaging 101 F. Six-foot roentgenograms showed a 59 per cent cardiothoracic ratio on admission, no change on March 20, and an increase to 75 per cent on April 26. On the latter date, there were typical physical signs of pericardial effusion, which proved to be serosanguinous in type. Miliary infiltration was first detected in the lung fields on April 26; the lesions increased in size in subsequent roentgenograms.

The first tracing obtained on March 5 (fig. 6C) showed an initial upstroke in all precordial leads. This R wave increased progressively from an amplitude of 1 mm. in  $V_1$  to 6 mm. in  $V_4$ , then fell off to 4 mm. in  $V_5$  and increased to 6 mm. in  $V_6$ . In view of the equiphase RS complex in  $V_5$ , the localized reduction in the amplitude of the R wave was

but measured 1 to 2 mm. in amplitude in Leads  $V_3$  and  $V_5$ . The localized reduction in the amplitude of the R wave in  $V_4$  could not be dismissed as a transitional zonal phenomenon because of the deep S wave, which exceeded the overall voltage of the equiphase RS deflection in  $V_5$ . The absolute and relative amplitudes of the R waves, as observed in the precordial leads of this case, would ordinarily raise the question of a healed patchy anteroapical infarct. This error was avoided in this instance because the clinical findings were known at the time of electrocardiographic interpretation.

The patient died of miliary tuberculosis on May 14. At autopsy the heart weighed 493 grams and showed a universal plastic tuberculous epicarditis, which reached a maximal thickness of 1 centimeter.

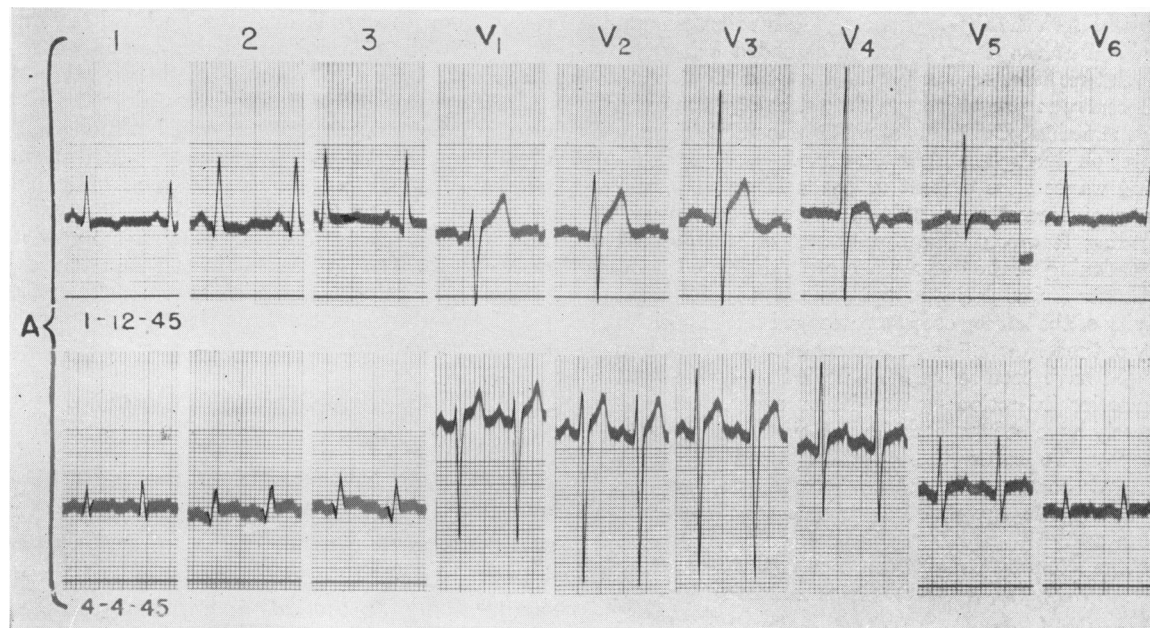


FIG. 7.—Serial electrocardiograms in Case 47.

considered a transitional zonal phenomenon. The T wave was isoelectric or low upright in all leads except  $V_4$ , where there were respiratory fluctuations between a low upright and shallowly inverted deflection. The significance of the T-wave patterns was not appreciated at the time, but in retrospect it seems likely that they were referable to pericarditis.

The tracing of April 29 showed a generalized reduction in QRS voltage, shallow inversion of T waves in Leads II and III, and flattening of the T waves in all other leads, consistent with pericardial effusion or constrictive pericarditis. The noteworthy feature of the tracing, which was responsible for the inclusion of the case in this article, was the localized reduction in the amplitude of the R wave in Lead  $V_4$ . The R wave was barely detectable in this lead,

The pericardial sac contained 250 cc. of serosanguinous fluid. The generalized and localized reduction in R wave could be correlated with the pericarditis.

*Case 47.*—The patient was a man 57 years of age, who had had hypertension for three years. He was first admitted to the hospital on Jan. 11, 1945, because of sudden vertigo. No cardiac glycosides were given. Electrocardiogram made on the following day and reproduced in fig. 7 showed initial R waves in all precordial leads. Those in Leads  $V_1$  and  $V_2$  were followed by deep, slightly widened S waves, elevated RS-T junctions, and tall upright T waves consistent with the changes produced by left ventricular hypertrophy in right precordial leads. The R waves in left ventricular Leads  $V_5$  and  $V_6$  were not abnormal in amplitude or duration, but

were followed by isoelectric RS-T junctions and inverted T waves suggestive, but not diagnostic, of left ventricular hypertrophy.

Lead  $V_4$  required special attention because of domelike elevation of the RS-T segment and cove-plane inversion of the T wave. The tall initial R wave was against myocardial infarction and the limitation of the cove-plane pattern to one lead was against pericarditis. The fact that the R wave in  $V_4$  resembled that in  $V_5$  and  $V_6$ , whereas the S wave was comparable to that in  $V_3$  and  $V_2$ , suggested that the electrode at position  $V_4$  was in the vicinity of the transitional zone and that the RS-T complex represented an approximately equal admixture of effects from the two ventricles. The first portion of the elevated RS-T segment resembled that in Leads  $V_3$  and  $V_2$  and was probably transmitted chiefly from the right ventricle, whereas the terminal portion of the T wave, which extended below the isoelectric line, resembled the inverted T wave in  $V_5$  and was probably transmitted chiefly from the left ventricle, as a result of counterclockwise cardiac rotation during mechanical systole.

Q waves were present in Leads II and III, and were of normal amplitude in reference to the succeeding R waves. The significance of slurring and broadening of the downstroke of  $Q_3$  depended upon whether it was derived from prolonged initial negativity of the left leg or from prolonged initial positivity of the left arm.<sup>43</sup> In the former event, the slurring might have been referable to healed subendocardial posterior infarction; in the latter event, it might merely have been referable to left ventricular hypertrophy. To settle the question, Lead  $aV_F$  was needed; however, the patient became symptom-free and left the hospital before this lead could be obtained.

The patient was symptom-free until the evening of April 3, 1945, when he was suddenly stricken with severe oppressive pain, confined to the retrosternal region, complicated by shock with blood pressure of 90/80. The electrocardiogram of April 4 was obtained fourteen hours after the onset of the pain. In the preliminary study, made without access to the previous tracing, a tentative diagnosis of recent posterior infarction was reached from the following findings in Leads  $aV_F$ , II, and III: a QR ratio of 25 to 40 per cent, elevation of the RS-T junctions and monophasic upright T waves. Complicating anterolateral pericarditis was postulated from the elevation of the RS-T segments and notched T waves in  $V_4$ ,  $V_5$ , and  $V_6$  in the presence of normal initial R waves.

Upon re-examination of the second tracing in the light of the original, further support to the diagnosis of recent anterolateral pericarditis was obtained from the decrease in amplitude of the R waves without change in contour of the QRS complex in the last three precordial leads. On the other hand, comparison of the two sets of limb

leads altered the interpretation of the second tracing. The Q waves were a remnant of those present in the first tracing and had shown a decrease in amplitude, rather than the increase expected from intercurrent posterior infarction. The downstroke of the Q wave in Lead  $aV_F$  was neither slurred nor prolonged. The reduction in the R waves was comparable to that in  $V_6$  and, along with the RS-T elevation, could be explained by pericarditis, in the absence of infarction. Although the error made in the original interpretation of the second tracing was corrected by restudy in the light of a previous tracing, this case serves to exemplify the difficulties in differentiation of the patterns of acute pericarditis and myocardial infarction. This history of sudden severe retrosternal pain followed by shock, together with a QRS-T pattern indicative of pericarditis rather than myocardial infarction, pointed towards hemopericardium from ruptured dissecting aneurysm.

Death occurred twenty-six hours after the last electrocardiogram. Autopsy revealed hemopericardium secondary to dissecting aneurysm. There was marked concentric left ventricular hypertrophy, but no evidence of recent or old myocardial infarction. The coronary vessels showed no signs of compression or occlusion. The autopsy findings adequately explained the history of sudden severe retrosternal pain followed by shock and the electrocardiographic signs of pericarditis.

#### DISTORTION OF THE QRS COMPLEX SECONDARY TO ARRHYTHMIAS

QRS complexes resembling the pattern of myocardial infarction may be found in certain arrhythmias, as a result of (1) an ectopic ventricular focus, (2) aberrant intraventricular conduction of a premature impulse of supraventricular origin, (3) fusion of an inverted auricular deflection with the beginning of the ventricular complex. The remaining cases have been selected to exemplify the foregoing situations.

##### *Ectopic Ventricular Beats.*

Attention to the possible diagnostic significance of the QRS-T pattern in ectopic ventricular beats has been directed by Dressler's case of posterior infarction.<sup>44</sup> The QRS-T pattern in beats of sinus origin was typical of left bundle branch block and was not indicative of infarction. The diagnosis was made from the presence of a deep Q wave, elevated RS-T junction and cove-negative T wave in ectopic beats in Lead III and was subsequently con-



firmed at necropsy. Since then, another case of left bundle branch block has been reported,<sup>45</sup> in which the diagnosis of anterior myocardial infarction was made from the QRS-T pattern of ectopic ventricular beats in precordial leads. On the other hand, an impulse originating from an ectopic ventricular focus directly beneath the precordial electrode may give rise to a QS or QR complex, an elevated RS-T segment, and inverted T wave, irrespective of the presence or absence of myocardial infarction. The error that might result from an attempt to draw diagnostic inferences from the QRS-T pattern in ventricular ectopic beats is illustrated by Case 48.

*Case 48.*—The patient, a woman 38 years of age, gave a history of fever and night sweats of three months duration and had physical and roentgen signs of pericardial effusion. Three hundred and fifty cc. of straw-colored fluid were removed prior to the electrocardiogram reproduced in figure 8.

A sinus mechanism was present, complicated by intermittent premature ventricular beats with short episodes of bigeminy. The QRS complexes of sinoauricular origin were consistent with a diagnosis of pericarditis, because of (1) initial R waves that were low in voltage, but normal in configuration in all leads; (2) T waves that were inverted in  $V_2$ ,  $V_3$ ,  $V_4$ , and  $V_5$  and isoelectric in the remaining leads. On the other hand, the QRS complexes of the premature ventricular beats in Lead  $V_3$  (second, fourth, and sixth cycles) were characterized by a deep, wide, slurred Q wave, a domelike RS-T segment and inverted T wave, and were comparable to those in Dressler's case.<sup>44</sup> Although the presence of such a pattern in beats of sinoauricular origin would have been considered pathognomonic of infarction, its limitation to ectopic ventricular beats nullified its diagnostic significance in the antemortem interpretation of the tracing.

Death occurred three weeks after the electrocardiogram. Autopsy revealed tuberculous pericarditis. The epicardium was approximately 1 cm. in thickness. The inflammatory process extended into the subepicardial zone, but spared the deeper layers of myocardium. There was no gross or microscopic evidence of myocardial infarction. The deep, broad Q wave in the premature ventricular beats of Lead  $V_3$  was probably a manifestation of an ectopic focus in the subepicardial layer.

#### *Ventricular Tachycardia.*

In the interpretation of electrocardiograms exhibiting sinus rhythm complicated by pre-

mature ventricular beats, one is less likely to err by disregarding the configuration of ectopic beats and depending entirely upon the QRS-T pattern of intervening sinus beats. When sustained ventricular tachycardia is present, there are no sinus impulses to serve as a guide and

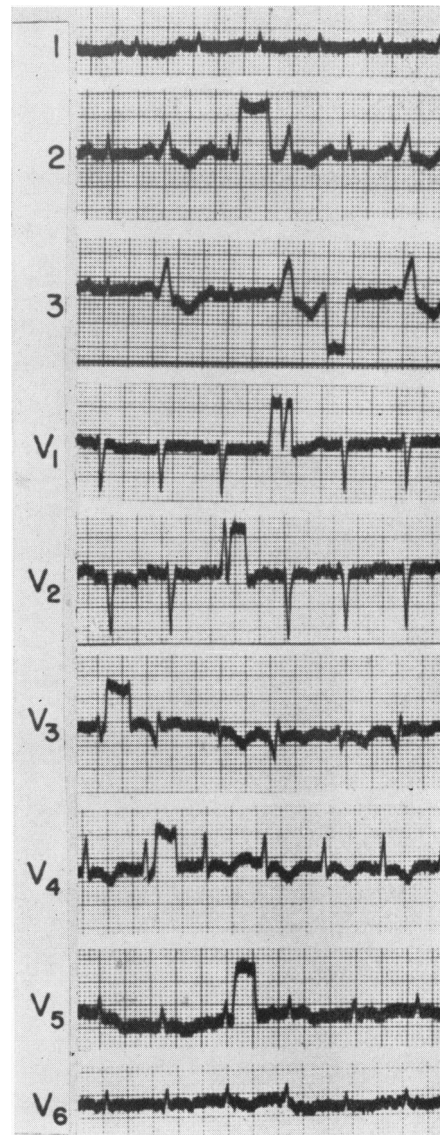


FIG. 8.—Electrocardiographic findings in Case 48.

one may be tempted to draw diagnostic inferences from QS or QR patterns, particularly in view of the fact that myocardial infarction is the commonest cause of this type of arrhythmia. The error from such deductions is exemplified by Case 49.

*Case 49.*—The patient was a man, 53 years of age, who began to have exertional and paroxysmal nocturnal dyspnea in the summer of 1942 and dependent edema the following autumn. He was admitted to the hospital with severe congestive failure in Jan. 1943. There was electrocardiographic evidence of left ventricular hypertrophy and nodal tachycardia, which later reverted to sinus rhythm. The patient was well compensated at discharge and was not again under observation until Sept. 18,

was favored partly because of the known presence of nodal tachycardia on the previous admission, but chiefly because of the absence of distinct f waves. Proceeding upon the assumption of a middle nodal tachycardia, the deep broad Q waves, late R wave, and RS-T elevation in Leads  $V_1$  and  $V_2$  were construed as evidence of septal infarction with right bundle branch block and the W-shaped QRS complexes in  $V_3$  and  $V_4$  were attributed to continuation of the lesion into the anteroseptal wall of the

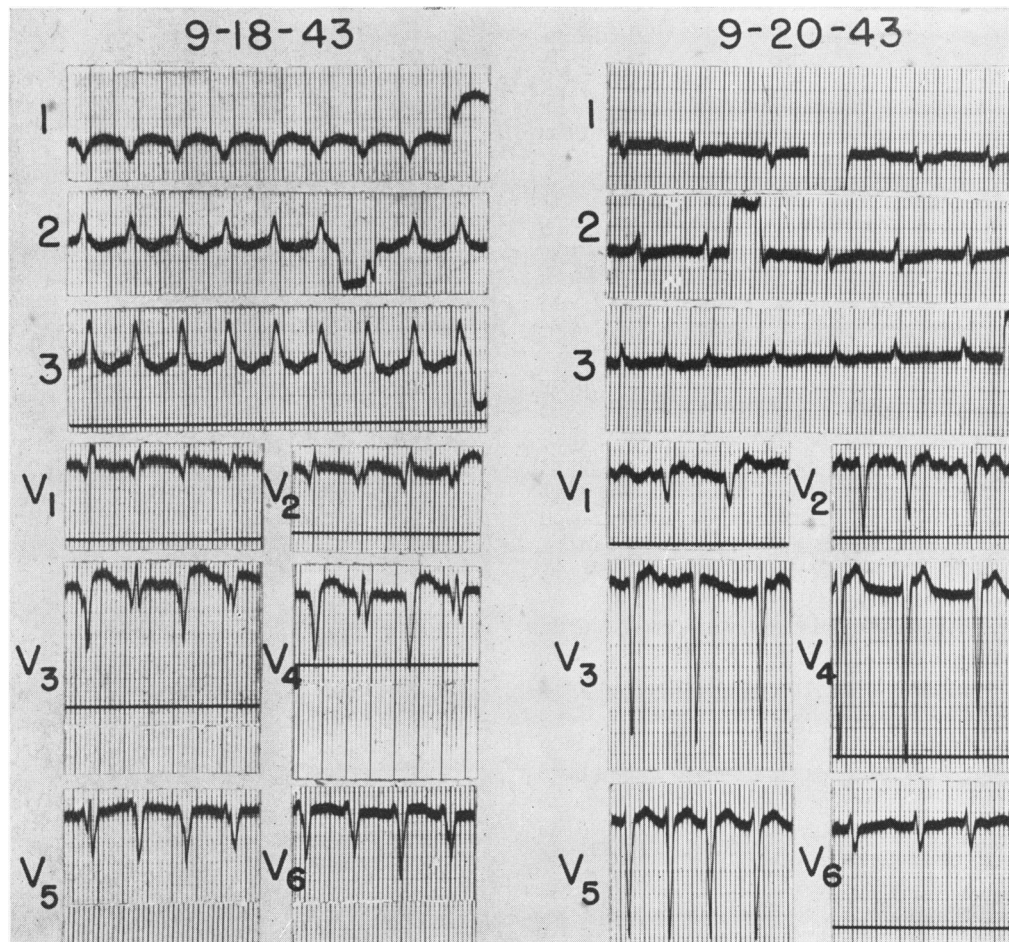


FIG. 9.—Electrocardiographic findings in Case 49.

1943, when he was brought to the hospital in coma. No history was obtainable. Cedilanid 1.6 mg. was given intravenously prior to the electrocardiogram.

The tracing of September 18 revealed no evidence of auricular activity, a regular ventricular rhythm of 150 per minute, and a QRS interval of 0.14 second (fig. 9). Two explanations were considered: (1) auricular fibrillation complicated by ventricular tachycardia, (2) middle nodal tachycardia with defective intraventricular conduction. When the tracing was first examined, the latter alternative

left ventricle. The QRS alternans in  $V_2$ ,  $V_3$  and  $V_4$  was also considered a manifestation of anteroseptal infarction.

The findings on September 20 (fig. 9) placed a different light both on the arrhythmia and the ventricular lesion. Distinct f waves were visible in  $V_1$  and  $V_2$  and the ventricular rhythm was totally irregular, indicating the presence of auricular fibrillation. The QRS interval had shortened to 0.10 second. All six precordial leads displayed an rS deflection. In the first three leads, the initial r



was minute and was followed by a broad, slurred S wave; in the last three leads, the r wave increased progressively at the expense of the S wave. The rS deflection in the first five leads indicated predominant transmission of the potential variations of the right ventricle to the left precordium; the small, almost equiphasic RS complex in  $V_6$  represented a manifestation of the transitional zone. The wide transmission of the potential variations of the right ventricle over the left precordium was due in part to right ventricular hypertrophy, in part to clockwise rotation of the heart. The depth and breadth of the S wave in these leads indicated left ventricular hypertrophy. Leads  $V_7$  and  $V_8$  were not obtained in this case, but would probably have furnished confirmatory evidence of left ventricular hypertrophy in the form of a prominent R wave with late peak, reciprocal to the S wave of Lead  $V_2$ .

In view of the findings on September 20, reconsideration was given to the tracing of September 18 and the diagnosis was changed to auricular fibrillation complicated by A-V block and ventricular tachycardia. Since the deep broad Q waves in the first four precordial leads on September 18 gave way to a distant initial R wave on September 20, when the ventricles were activated by impulses of auricular origin, it was concluded that these Q waves were referable to an ectopic ventricular focus rather than to myocardial infarction. Both the ventricular tachycardia and QRS alternans probably represented manifestations of digitalis intoxication and could have been produced by the intravenous injection of 1.6 mg. Cedilanid, particularly if the patient had been receiving cardiac glycosides prior to admission.

Death occurred on September 21. At autopsy the heart weighed 690 grams and exhibited left ventricular hypertrophy and secondary right ventricular dilatation and hypertrophy. The coronary arteries were of normal caliber and no evidence of myocardial infarction was found. Thus, an erroneous diagnosis consequent upon the present of ventricular tachycardia was averted by a second tracing, taken after resumption of ventricular activation by impulses of auricular origin.

#### *Aberrant Intraventricular Conduction of Premature Auricular Beats*

This has been exemplified by the first tracing obtained on Case 41 (fig. 3). Premature auricular beats in Leads  $aV_F$ , II and III were followed by QR deflections that conformed with the pattern of posterior infarction both in respect to the duration of the descending limb of the Q wave and the relative amplitudes of the Q and R waves. A diagnosis of posterior infarction would have been justified if beats of

sinoauricular origin in the same leads had displayed comparable QR deflections. Since RS deflections were registered in all cycles of sinus origin in Leads  $aV_F$ , II and III, the question arose as to whether the QR complexes associated with the ectopic auricular beats were manifestations of aberrant conduction in the absence of myocardial infarction or other ventricular lesion. Since repolarization is normally completed earlier in the anterior than in the posterior wall of the ventricles, it is possible for a premature auricular impulse to reach the ventricles immediately after the anterior wall has passed out of the refractory state, but while the posterior wall is still unresponsive. During the period while the impulse is activating the anterior, but is held up in the posterior wall, negative cavity potentials are transmitted through the posterior wall to the surface, to be recorded as abnormal Q waves in Leads  $aV_F$ , II and III. The fact that the ectopic auricular beats in Patient 41 were so premature that the ventricular response began 0.05 second prior to the end of the T wave of the preceding cycle indicated that aberrant intraventricular conduction in the absence of infarction could have accounted for the abnormal Q waves in Leads  $aV_F$ , II and III of the ectopic beats. Autopsy excluded the possibility of infarction, but did reveal an ischemia of the entire circumference of the subendocardial layer of the left ventricle. Whether or not the ischemia accentuated the normal difference in time of recovery from the refractory state in the anterior and posterior walls is unknown.

#### *Fusion of a P Wave with the First Portion of the QRS Complex*

The possibility of mistaking an inverted auricular deflection for a Q wave has been mentioned,<sup>46</sup> and is exemplified by Case 50.

*Case 50.*—The patient, a clerk 49 years of age, was admitted to the hospital on April 9, after three weeks of incapacitation because of progressive orthopnea, complicated by repeated hemoptyses. Past history disclosed exertional dyspnea for five years and retrosternal burning on walking against a cold wind during the preceding winter. There were physical signs of mitral and aortic stenosis and insufficiency.

The electrocardiogram reproduced in figure 10 was one of a series and was obtained after digitalization. Since the interpretation of this tracing would have been rendered more difficult if Lead  $V_{3R}$  had not been available, an analysis will first be made of the remaining leads. Casual inspection of Lead

amplitude. In the remaining precordial leads, the QRS began with an upstroke and the R wave steadily increased at the expense of the S wave as the electrode was moved towards the left. The R/S ratio thus failed to reveal evidence of preponderant hypertrophy of the right ventricle.

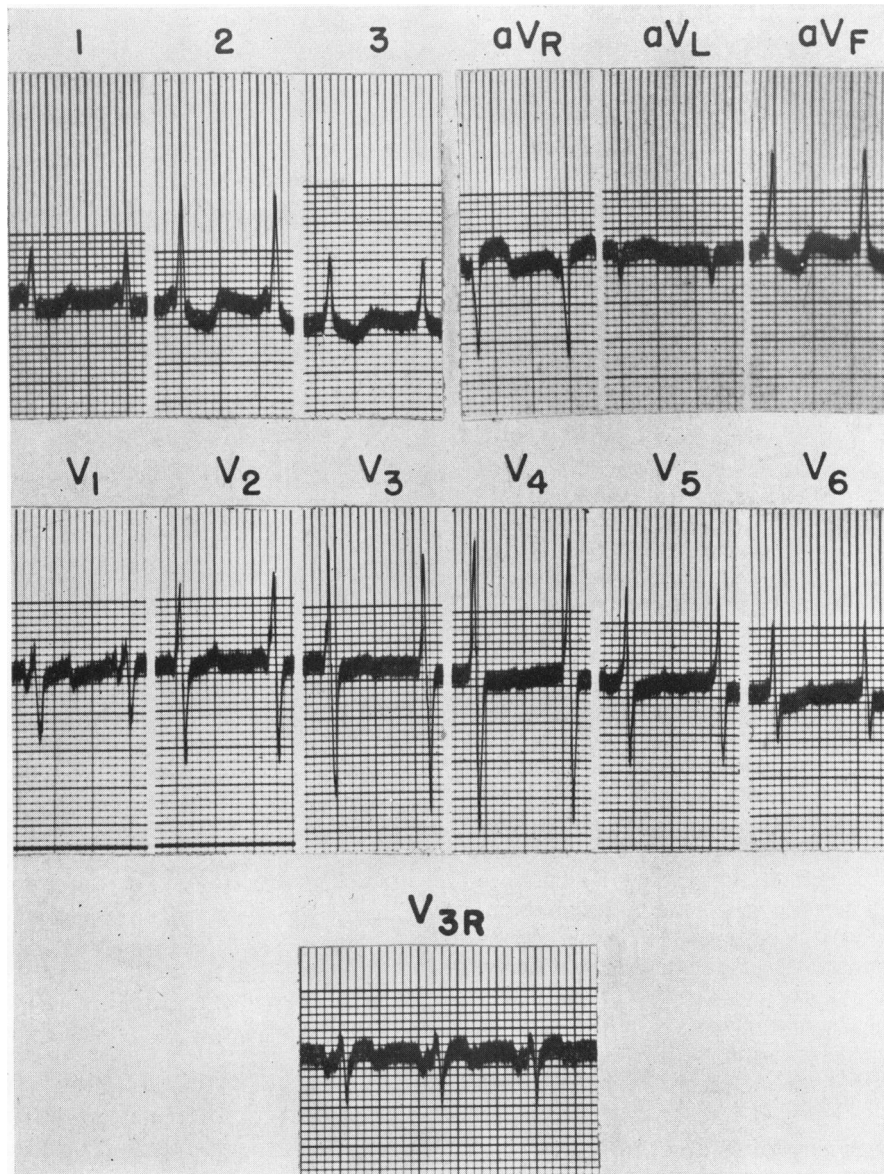


FIG. 10.—Electrocardiographic findings in Case 50.

$V_1$  showed a precipitous initial downstroke, 2 mm. in depth and 0.02 second in duration, followed by a splintered R wave reaching 3 mm. above the isoelectric line and then by an S wave 7 mm. deep. A barely discernible initial downstroke was found in  $V_2$ , followed by an equiphasic RS complex, each component being approximately 12 mm. in

If the initial downstroke in  $V_1$  and  $V_2$  represented a Q wave, a diagnosis of old septal infarction would have been justified.<sup>47</sup> Comparison of measurements of the QRS interval in various precordial leads provides a useful method for determining whether or not the initial downstroke in  $V_1$  and  $V_2$  is a part of the ventricular complex. When differences exist,



the longest measurement is generally obtained in leads directly over the ventricles (such as  $V_3$  and  $V_4$ ) and slightly shorter measurements are obtained in leads at a distance, such as  $V_1$  and/or  $V_6$ , owing to transmission losses at onset or end of ventricular activation. The interval from the beginning of the initial downstroke to the end of the S wave in  $V_1$  measured 0.12 second and was 0.03 to 0.04 second longer than the interval in  $V_3$  and  $V_4$ . This observation indicated that the initial downstroke was not a part of the QRS complex, but rather an antecedent P wave. The resemblance of the downstroke of this P wave to the exceptionally steep descent of the T wave suggested that the latter was due to a superimposed P wave. This was confirmed by the fact that the time interval between these two downstrokes was exactly one-half of a cycle length.

Although the correct diagnosis could be reached from a careful analysis of Lead  $V_1$ , it was evident from a glance at Lead  $V_{3R}$ . The inverted and notched deflection immediately preceding the RS complex was unmistakably a P wave and the presence of a similar notch on the T wave indicated a second superimposed auricular deflection. The shape of the P waves and the intervening isoelectric interval indicated the presence of auricular tachycardia and the A-V ratio indicated a 2:1 block. A similar rhythm was found in five other tracings obtained over a span of sixteen days. The ease of diagnosis from Lead  $V_{3R}$ , the possibility of mistaking the P for Q waves from a casual inspection of Leads  $V_1$  and  $V_2$  and of detecting the abnormal rhythm from a more careful analysis of the same lead, and the difficulty or impossibility of diagnosis from other leads were also observed in other tracings.

Death occurred as a result of multiple pulmonary infarcts. At autopsy the heart weighed 554 grams and showed right and left ventricular hypertrophy, associated with rheumatic mitral and aortic valvulitis. Both atria were markedly dilated. The coronary vessels were of normal caliber and no evidence of myocardial infarction was found.

#### SUMMARY

Certain QRS-T patterns suggestive of myocardial infarction, but actually referable to alterations of blood potassium, to myocardial ischemia, to subepicardial myocarditis, or to distortion from arrhythmia are illustrated by cases in which the possibility of myocardial infarction was excluded at autopsy.

Precipitous fall in blood potassium to low levels may be manifested by RS-T depression and T-wave inversion resembling that associated with acute subendocardial infarction. Extreme hyperkalemia may cause marked

widening of the terminal portion of the QRS complex and fusion with the T wave to form a pattern that may be mistaken for that of myocardial infarction, complicated by bundle branch block.

The problem in differential diagnosis between acute subendocardial infarction and an acute surgical abdomen complicated by shock and the error that may result from overemphasis of electrocardiographic findings is exemplified by a case showing marked and progressive RS-T depression due to myocardial ischemia without infarction, secondary to gangrene of the ileum.

Rapidly evolving cove-plane inversion of the T waves associated with acute myocardial ischemia of varying cause and with acute subepicardial myocarditis is exemplified and differentiated from that accompanying acute myocardial infarction.

The following electrocardiographic patterns associated with subepicardial myocarditis and pericarditis may be mistaken for those of myocardial infarction and are differentiated with the aid of illustrative cases: (1) localized elevation of the RS-T junction and/or cove-plane inversion of the T wave in the presence of an initial R wave of normal or low voltage, (2) abnormal upward displacement of the RS-T segment and/or cove-plane inversion of the T wave in complexes exhibiting a distinct Q wave and a normal to borderline Q/R ratio, (3) localized reduction in the amplitude of the R wave in a given lead below that attained in adjacent leads to the right and left.

The errors that might result from attempts to draw diagnostic inferences from the registration of deep Q waves and/or cove-negative T waves in premature ventricular beats or in ventricular tachycardia are brought out by suitable examples. Furthermore, premature auricular beats may be conducted aberrantly through the uninfarcted ventricles, leading to the registration of abnormal QR patterns, simulating those recorded in sinoauricular beats in the presence of infarction. The fusion of a sharply inverted ectopic P wave in  $V_1$  with the first portion of the QRS to produce a triphasic deflection resembling the findings in septal infarction is also demonstrated.

## ACKNOWLEDGMENT

The autopsy findings were furnished by Drs. B. E. Stofer and T. Hiratzka of the department of Pathology. Dr. Howard Klein assisted in the collection of the electrocardiographic material. The tracings were retouched by Miss Evelyn Erickson and Miss Geraldine Chesney.

## REFERENCES

- <sup>1</sup> MYERS, G. B.: QRS-T patterns in multiple precordial leads that may be mistaken for myocardial infarction. I. Left ventricular hypertrophy and dilatation. *Circulation* **1**: 844, 1950.
- <sup>2</sup> —: *Ibid.* II. Right ventricular hypertrophy and dilatation. *Circulation* **1**: 860, 1950.
- <sup>3</sup> —: *Ibid.* III. Bundle branch block. *Circulation* (This issue, p. 60).
- <sup>4</sup> THOMSON, W. A. R.: The effect of potassium on the heart of man. *Brit. Heart J.* **1**: 269, 1939.
- <sup>5</sup> STEWART, H. J., AND SMITH, J. J.: Changes in electrocardiogram and in cardiac rhythm during therapeutic use of potassium salts. *Am. J. M. Sc.* **201**: 177, 1941.
- <sup>6</sup> FINCH, C. A., AND MARCHAND, J. F.: Cardiac arrest by action of potassium. *Am. J. Med.* **206**: 507, 1943.
- <sup>7</sup> KEITH, N. M., BURCHELL, H. B., AND BAGGENSTOSS, A. H.: Electrocardiographic changes in uremia associated with a high concentration of serum potassium. *Am. Heart J.* **27**: 817, 1944.
- <sup>8</sup> FINCH, C. A., SAWYER, C. G., AND FLYNN, J. M.: Clinical syndrome of potassium intoxication. *Am. J. Med.* **1**: 337, 1946.
- <sup>9</sup> STEWART, H. J., SMITH, J. J., AND MILHORAT, A. T.: Electrocardiographic and serum potassium changes in familial periodic paralysis. *Am. J. M. Sc.* **199**: 789, 1940.
- <sup>10</sup> STOLL, B., AND NISSEWITZ, S.: Electrocardiographic studies in case of periodic paralysis. *Arch. Int. Med.* **67**: 755, 1941.
- <sup>11</sup> BROWN, M. R., CURRENS, J. H., AND MARCHAND, J. F.: Muscular paralysis and electrocardiographic abnormalities resulting from potassium loss in chronic nephritis. *J. A. M. A.* **124**: 545, 1944.
- <sup>12</sup> HOLLER, J. W.: Potassium deficiency occurring during treatment of diabetic acidosis. *J. A. M. A.* **131**: 1186, 1946.
- <sup>13</sup> MARTIN, H. E., AND WORTMAN, M.: Electrolyte changes and the electrocardiogram in diabetic acidosis. *Am. Heart J.* **34**: 646, 1947.
- <sup>14</sup> BARKER, P. S., SHRADER, E. L., AND RONZANI, E.: The effects of alkalosis and of acidosis upon the human electrocardiogram. *Am. Heart J.* **17**: 169, 1939.
- <sup>15</sup> FEIL, H., AND SIEGEL, M. L.: Electrocardiographic changes during attacks of angina pectoris. *Am. J. M. Sc.* **175**: 255, 1928.
- <sup>16</sup> GOLDHAMMER, S., AND SCHERF, D.: Elektrokardiographische Untersuchungen bei Kranken mit Angina Pectoris. *Ztschr. f. klin. Med.* **122**: 134, 1932.
- <sup>17</sup> LEVY, R. L., BRUENN, H. G., AND RUSSELL, N. G.: The use of electrocardiographic changes caused by induced anoxemia as a test for coronary insufficiency. *Am. J. M. Sc.* **197**: 241, 1939.
- <sup>18</sup> WILSON, F. N., AND JOHNSTON, F. D.: The occurrence in angina pectoris of electrocardiographic changes similar in magnitude and in kind to those produced by myocardial infarction. *Am. Heart J.* **22**: 64, 1941.
- <sup>19</sup> BATTRO, A., AND ARRAYA, E.: Importance of precordial leads in electrocardiograms after exertion in angina pectoris; action of certain drugs (Trinitrin, aminophylline and papaverine). *Am. Heart J.* **33**: 723, 1947.
- <sup>20</sup> HAUSNER, E., AND SCHERF, D.: Über Angina Pectoris—Probleme. *Ztschr. f. klin. Med.* **126**: 166, 1933.
- <sup>21</sup> BRYANT, J. M., AND WOOD, J. E.: Tobacco angina; an electrocardiographic study. *Am. Heart J.* **34**: 20, 1947.
- <sup>22</sup> MURPHY, F. D., AND LIVEZEY, M. M.: Electrocardiographic changes simulating those of acute myocardial infarction in a case of perforated peptic ulcer. *Am. Heart J.* **28**: 533, 1944.
- <sup>23</sup> GATTESMAN, J., CASTON, D., AND BELLER, A. J.: Changes in electrocardiogram induced by acute pancreatitis. *J. A. M. A.* **123**: 892, 1943.
- <sup>24</sup> GUBNER, R. S.: Electrocardiographic changes in abdominal disease. *J. A. M. A.* **124**: 122, 1944.
- <sup>25</sup> BLUMGART, H. L., HOFF, H. E., LANDOWNE, M., AND SCHLESINGER, M. J.: Experimental studies on effect of temporary occlusion of coronary arteries in producing persistent electrocardiographic changes. *Am. J. M. Sc.* **194**: 493, 1937.
- <sup>26</sup> BAYLEY, R. H., AND LA DUE, J. S.: Electrocardiographic changes of impending infarction and the ischemia-injury pattern produced in the dog by total and subtotal occlusion of a coronary artery. *Am. Heart J.* **28**: 54, 1944.
- <sup>27</sup> BAYLEY, R. H., AND LA DUE, J. S.: Differentiation of the electrocardiographic changes produced in the dog by prolonged temporary occlusion of a coronary artery from those produced by post-operative pericarditis. *Am. Heart J.* **28**: 233, 1944.
- <sup>28</sup> BARNES, A. R., AND BURCHELL, H. B.: Acute pericarditis simulating acute coronary occlusion. *Am. Heart J.* **23**: 247, 1942.
- <sup>29</sup> JONES, E., AND BEDFORD, D. E.: Syphilitic angina pectoris. *Brit. Heart J.* **5**: 107, 1943.
- <sup>30</sup> SCHERF, D., AND KLOTZ, S. D.: Electrocardiographic changes after acute loss of blood. *Ann. Int. Med.* **20**: 438, 1944.
- <sup>31</sup> PORTE, D., AND PARDEE, H. E. B.: The occurrence of the coronary T wave in rheumatic pericarditis. *Am. Heart J.* **4**: 584, 1929.



- <sup>32</sup> SCOTT, R. W., FEIL, H. S., AND KATZ, L. N.: The electrocardiogram in pericardial effusion. *Am. Heart J.* **5**: 68, 1929.
- <sup>33</sup> HOLZMANN, M.: Elektrokardiographische Befunde bei Perikarditis. *Ztschr. f. klin. Med.* **128**: 731, 1935.
- <sup>34</sup> SCHWAB, E. H., AND HERRMANN, G.: Alterations of electrocardiogram in diseases of pericardium. *Arch. Int. Med.* **55**: 917, 1935.
- <sup>35</sup> VANDER VEER, J. B., AND NORRIS, R. F.: Electrocardiographic changes in acute pericarditis; clinical and pathological study. *Am. Heart J.* **14**: 31, 1937.
- <sup>36</sup> BELLET, S., AND McMILLAN, T. M.: Electrocardiographic patterns in acute pericarditis. *Arch. Int. Med.* **61**: 381, 1938.
- <sup>37</sup> NOTH, P. H., AND BARNES, A. R.: Electrocardiographic changes associated with pericarditis. *Arch. Int. Med.* **65**: 291, 1940.
- <sup>38</sup> WEINSTEIN, M.: Stab wound of the heart. *J. A. M. A.* **122**: 664, 1943.
- <sup>39</sup> HARVEY, A. M., AND BILLINGS, F. T.: Coronary occlusion after fever therapy for sulfonamide resistant gonorrheal urethritis. *Am. Heart J.* **29**: 205, 1945.
- <sup>40</sup> MIDDLETON, H. N.: Electrocardiographic studies of gunshot and stab wounds of heart. *Am. Heart J.* **34**: 899, 1947.
- <sup>41</sup> BURCHELL, H. B., BARNES, A. R., AND MANN, F. C.: The electrocardiographic picture of experimental localized pericarditis. *Am. Heart J.* **18**: 133, 1939.
- <sup>42</sup> DEARING, W. H., BARNES, A. R., AND ESSEX, H. E.: Experiments with calculated therapeutic and toxic doses of digitalis; effects on electrocardiogram. *Am. Heart J.* **25**: 665, 1943.
- <sup>43</sup> MYERS, G. B., AND OREN, B. G.: Use of augmented unipolar left leg lead in differentiation of normal from abnormal Q wave in standard lead III. *Am. Heart J.* **29**: 708, 1945.
- <sup>44</sup> DRESSLER, W.: A case of myocardial infarction masked by bundle branch block but revealed by occasional premature ventricular beats. *Am. J. M. Sc.* **206**: 361, 1943.
- <sup>45</sup> SIMONSEN, E., ENZER, N., AND GOODMAN, J. S.: Coronary insufficiency, revealed by ectopic nodal and ventricular beats in presence of left bundle branch block. *Am. J. M. Sc.* **209**: 349, 1945.
- <sup>46</sup> KISCH, B.: Extrasystoles in experimentally produced hypertension. *Exper. Med. & Surg.* **4**: 319, 1946.
- <sup>47</sup> MYERS, G. B., KLEIN, H. A., AND HIRATZKA, T.: Correlation of electrocardiographic and pathologic findings in infarction of the interventricular septum and right ventricle. *Am. Heart J.* **37**: 720, 1949.

**Other QRS-T Patterns that May Be Mistaken for Myocardial Infarction: IV.  
Alterations in Blood Potassium; Myocardial Ischemia; Subepicardial Myocarditis;  
Distortion Associated with Arrhythmias**  
GORDON B. MYERS

*Circulation*. 1950;2:75-93

doi: 10.1161/01.CIR.2.1.75

*Circulation* is published by the American Heart Association, 7272 Greenville Avenue, Dallas, TX 75231

Copyright © 1950 American Heart Association, Inc. All rights reserved.

Print ISSN: 0009-7322. Online ISSN: 1524-4539

The online version of this article, along with updated information and services, is located on the World Wide Web at:

<http://circ.ahajournals.org/content/2/1/75>

**Permissions:** Requests for permissions to reproduce figures, tables, or portions of articles originally published in *Circulation* can be obtained via RightsLink, a service of the Copyright Clearance Center, not the Editorial Office. Once the online version of the published article for which permission is being requested is located, click Request Permissions in the middle column of the Web page under Services. Further information about this process is available in the [Permissions and Rights Question and Answer](#) document.

**Reprints:** Information about reprints can be found online at:

<http://www.lww.com/reprints>

**Subscriptions:** Information about subscribing to *Circulation* is online at:

<http://circ.ahajournals.org/subscriptions/>