

# Wide Complex Tachycardia on Telemetry

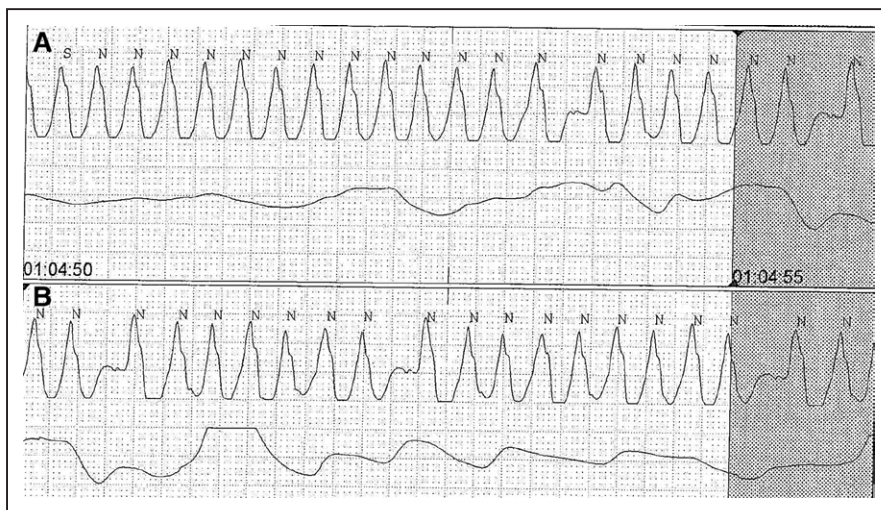
## What Is the Diagnosis?

### ECG CHALLENGE

A 76-year-old woman with a history of hypertension, diabetes mellitus, dilated non-ischemic cardiomyopathy (ejection fraction of 35%), and normal pressure hydrocephalus for which she had received a ventriculoperitoneal shunt 5 years ago was found unresponsive at home. She was intubated for airway protection in the field and was admitted to an outside hospital where an extensive neurological workup did not reveal the cause of her unconsciousness. She was transferred to our hospital to evaluate a potential cardiac etiology for her symptoms. On admission, she was noted to have an incessant wide complex tachycardia at a rate of  $\approx 230$  beats per minute on telemetry (Figure 1A and 1B). What is the most likely diagnosis, and what is the cause for the intermittent pauses during tachycardia?

Please turn the page to read the diagnosis.

Santosh K. Padala, MD  
Gautham Kalahasty, MD  
Kenneth A. Ellenbogen, MD



**Figure 1. Telemetry strip showing a wide complex tachycardia.**

**A and B** show a wide complex tachycardia at a rate of  $\approx 230$  beats per minute with intermittent pauses.

**Correspondence to:** Kenneth A. Ellenbogen, MD, Gateway Building, 3rd Floor, 3-216, 1200 East Marshall Street, Richmond, VA 23219. E-mail kenneth.ellenbogen@vcuhealth.org

**Key Words:** AV block ■  
supraventricular tachycardia ■  
Wenckebach conduction

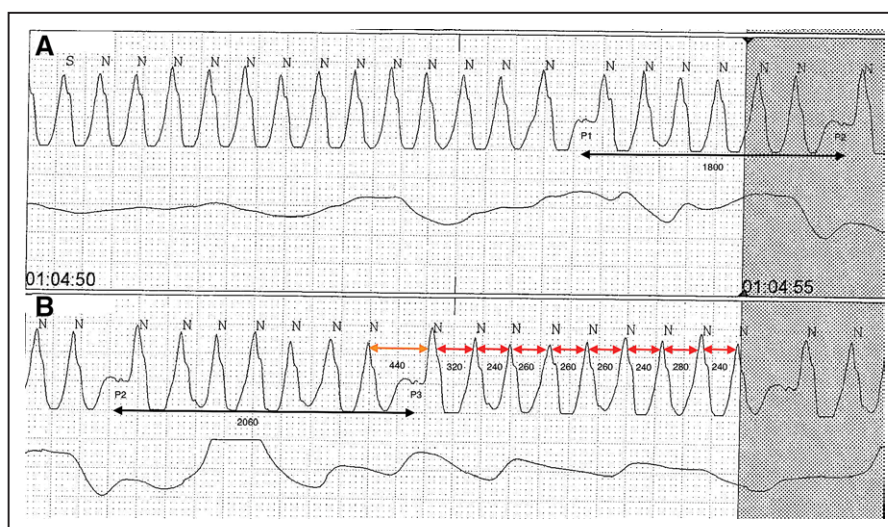
© 2017 American Heart Association, Inc.

## RESPONSE TO ECG CHALLENGE

Differential diagnosis of this wide complex tachycardia included supraventricular tachycardia with aberrancy (functional or preexisting bundle-branch block), preexcited tachycardia (antidromic tachycardia or supraventricular tachycardia with bystander accessory pathway conduction), paced rhythm, and ventricular tachycardia. A methodical approach to the telemetry strip may yield diagnosis. The baseline ECG showed sinus rhythm with left bundle-branch block. Careful analysis of the telemetry strip shows a rapid, wide complex tachycardia with group beating of QRS complexes and slight variability in the tachycardia cycle length. P waves are not seen before each QRS complex. Sinus tachycardia is unlikely based on rate alone. Antidromic tachycardia is unlikely because the tachycardia continues despite atrioventricular (AV) block. The finding of discrete P waves and group beating rules out atrial fibrillation. Ventricular tachycardia should be strongly suspected given her presentation of loss of consciousness in the setting of a low ejection fraction. Differentiating ventricular tachycardia from supraventricular tachycardia with aberrancy is imperative, because they have different therapeutic and prognostic implications. However, it can be very challenging to differentiate between these options with only a telemetry strip because of the limited number of electrocardiographic leads available. Furthermore, the frequently used electrocardiographic signs to distinguish ventricular tachycardia from supraventricular tachycardia with aberrancy are seen in less than half of the cases.<sup>1,2</sup> In the present rhythm there is no evidence of capture or fusion beats. There is no evidence of AV dissociation at

the onset of tachycardia (eg, dissociated P wave at tachycardia onset) because the PR interval is constant at the beginning of the tachycardia and after each pause.<sup>2</sup> The intermittent P waves seen during the tachycardia may falsely give an impression of AV dissociation during tachycardia and mislead one to the diagnosis of ventricular tachycardia. The measured P1P2 interval in Figure 2A was  $\approx 1800$  ms. In Figure 2B, P2P3 interval was 2060 ms. The difference between P2P3 and P1P2 intervals was 260 ms, which is approximately equal to the tachycardia cycle length. This suggests 1:1 P/QRS relationship until AV block occurs. P waves are difficult to discern before each QRS because they are buried in the wide QRS complexes, but they are seen clearly when there is a pause during AV block. This favors the diagnosis of atrial tachycardia with intermittent and variable block.

The mechanism of pauses in the present rhythm was Mobitz type I AV block (Wenckebach phenomenon). Wenckebach phenomenon can be typical or atypical. Typical Wenckebach periodicity is characterized by (1) gradual lengthening of the PR interval until a pause where the P wave is not followed by a QRS complex; (2) gradual shortening of the RR interval until a pause (this is because the lengthening of the PR interval occurs at gradually decreasing increments); (3) the pause following a nonconducted P wave is less than the sum of 2 RR intervals of any consecutively conducted beats; (4) the PR interval after the block is short in comparison with the PR interval just preceding the block; and (5) group beating.<sup>3</sup> Typical Wenckebach periodicity is less common than the atypical form and is noted in  $<50\%$  of type 1 AV block tracings. Atypical Wenckebach patterns do not follow the above-



**Figure 2. Telemetry strip showing a wide complex tachycardia.**

Note the long Wenckebach periods of 7:6 in **A** and 8:7 and 10:9, respectively, in **B**. Black arrows (**A** and **B**) indicate the measured interval between P1P2 and P2P3 in milliseconds. Red arrows (**B**) indicate the measured interval between 2 consecutive RR in milliseconds. Yellow arrow (**B**) is the measured interval during the pause in milliseconds.

mentioned typical features. As such, prolongation of the PR interval or shortening of the RR interval may not be progressive. The largest increment in the PR interval may be seen just before the block as opposed to the second conducted impulse after the pause in typical pattern. This is likely because of changes in autonomic tone affecting AV nodal conduction, thus modifying the typical Wenckebach periodicity. Atypical Wenckebach patterns are more often seen with longer Wenckebach periodicity (>6:5) as seen here.<sup>3</sup> In Figure 2A and 2B there was no clear evidence of gradual PR prolongation or gradual RR shortening before the pause. The findings that favor the Wenckebach phenomenon in the present rhythm are group beating and the pause during the AV block that is less than twice the RR interval during conducted beats (yellow arrow, Figure 2B).

## DISCLOSURES

None.

## FOOTNOTES

*Circulation* is available at <http://circ.ahajournals.org>.

## REFERENCES

1. Brady WJ, Skiles J. Wide QRS complex tachycardia: ECG differential diagnosis. *Am J Emerg Med*. 1999;17:376–381.
2. Padala SK, Sidhu MS, Brown JR, Zipursky JS, Steckman DA, Parikh DR, Greenberg ML. Non-sustained wide complex tachycardia: an underappreciated sign to aid in diagnosis. *Europace*. 2016;18:1069–1076. doi: 10.1093/europace/euv273.
3. Issa ZF, Miller JM, Zipes DP. Atrioventricular conduction abnormalities. In: *Clinical Arrhythmology and Electrophysiology: a Companion to Braunwald's Heart Disease*. 2nd ed. Philadelphia, PA: Elsevier; 2012: 175–193.

## Wide Complex Tachycardia on Telemetry: What Is the Diagnosis?

Santosh K. Padala, Gautham Kalahasty and Kenneth A. Ellenbogen

*Circulation*. 2017;135:904-906

doi: 10.1161/CIRCULATIONAHA.117.027176

*Circulation* is published by the American Heart Association, 7272 Greenville Avenue, Dallas, TX 75231

Copyright © 2017 American Heart Association, Inc. All rights reserved.

Print ISSN: 0009-7322. Online ISSN: 1524-4539

The online version of this article, along with updated information and services, is located on the World Wide Web at:

<http://circ.ahajournals.org/content/135/9/904>

**Permissions:** Requests for permissions to reproduce figures, tables, or portions of articles originally published in *Circulation* can be obtained via RightsLink, a service of the Copyright Clearance Center, not the Editorial Office. Once the online version of the published article for which permission is being requested is located, click Request Permissions in the middle column of the Web page under Services. Further information about this process is available in the [Permissions and Rights Question and Answer](#) document.

**Reprints:** Information about reprints can be found online at:  
<http://www.lww.com/reprints>

**Subscriptions:** Information about subscribing to *Circulation* is online at:  
<http://circ.ahajournals.org/subscriptions/>