

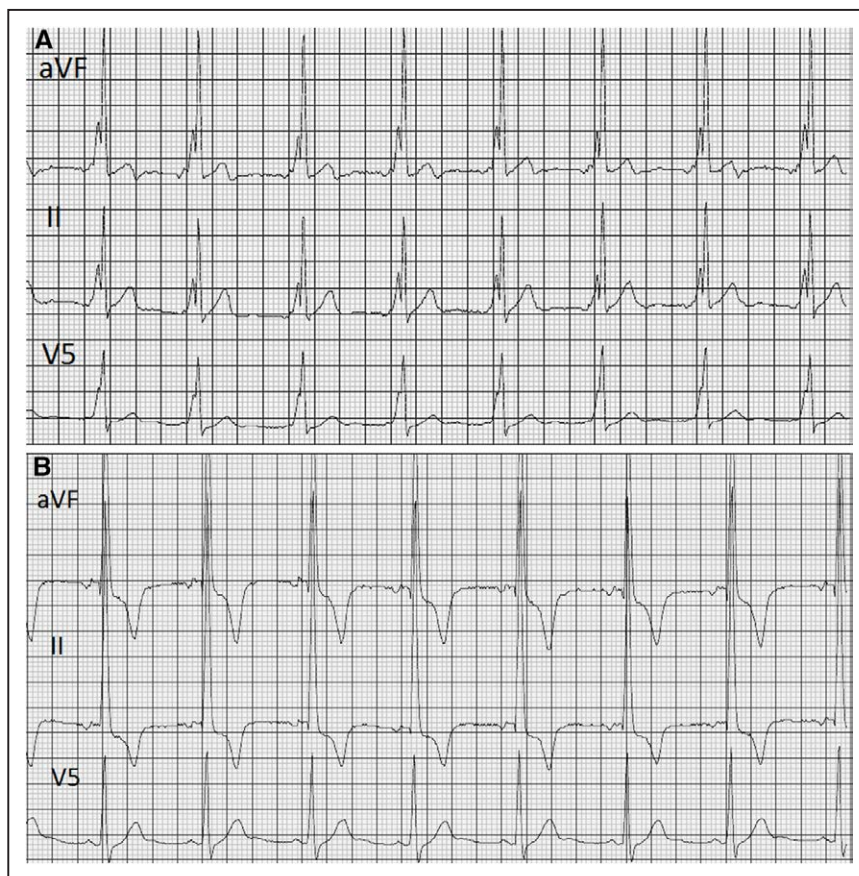
# Chest Pain and T-Wave Inversions in a 56-Year-Old Man

## ECG CHALLENGE

A 56-year-old man presented to cardiology clinic with daily episodes of chest heaviness and discomfort. He underwent an echocardiogram, which showed no evidence of structural heart disease. An exercise nuclear stress test showed average functional capacity and normal perfusion. Because of his daily symptoms, the patient wore a 24-hour Holter monitor (Figure 1A), which showed multiple episodes of T-wave inversions (Figure 1B), inconsistently associated with his symptoms of chest tightness. Because of these symptoms, he underwent coronary angiography, which showed minimal coronary artery disease. What is the mechanism of the T-wave inversions seen on Holter?

Please turn the page to read the diagnosis.

Nishant Verma, MD, MPH  
Bradley P. Knight, MD



**Figure 1. Twenty-four hour Holter monitor obtained due to intermittent chest pain.** A and B, A 24-hour Holter monitor was obtained to evaluate daily chest pain. Multiple instances of intermittent T-wave inversions were inconsistently associated with chest pain.

**Correspondence to:** Nishant Verma, MD, MPH, 251 East Huron St, Feinberg 8-503, Chicago, IL 60611. E-mail [nverma1@nm.org](mailto:nverma1@nm.org)

© 2017 American Heart Association, Inc.

## RESPONSE TO ECG CHALLENGE

The patient had a known diagnosis of Wolf-Parkinson-White syndrome, and his baseline 12-lead electrocardiogram (ECG) showed preexcitation consistent with a septal bypass tract (Figure 2A). The Holter monitor showed intermittent loss of preexcitation throughout the study. This finding on ambulatory monitoring is reassuring for a bypass tract incapable of conducting atrial fibrillation rapidly and, thus, at low risk of sudden cardiac death. Additionally, the loss of preexcitation in this case is associated with the development of T-wave inversions (TWIs), a form of cardiac memory.<sup>1</sup>

Cardiac memory refers to persistent T-wave changes on the ECG usually seen on the transition from a wide QRS rhythm to a normal QRS duration; these T-wave changes eventually normalize but can persist from weeks to >1 month in some cases. In cases of cardiac memory, the abnormal T-wave of the narrow-complex QRS during sinus rhythm follows the same direction as the QRS complex during the preceding wide QRS rhythm. The amplitude of the T-waves increases with longer periods of abnormal conduction, and repeated episodes result in more rapid and prominent T-wave changes.<sup>2</sup> Cardiac memory was first described in the setting of ventricular pacing<sup>3</sup> but has been seen in multiple other clinical scenarios, including preexcitation, transient bundle-branch block, and ventricular arrhythmias. This phenomenon is thought to reflect an adaptive response to changes in both electric ventricular repolarization and mechanical ventricular activation that occur with normalization of the QRS. The clinical significance and potential utility of cardiac memory continues to be explored.

TWIs are the most obvious manifestation on the ECG and are often misdiagnosed as pathological; however, other leads may show changes in T-wave amplitude and direction that are equally important. Distinguishing pacing-induced TWIs from ischemia can be challenging. However, the combination of a positive T-wave in

lead aVL, positive or isoelectric T-wave in lead I, and a greater degree of TWIs in the precordial leads relative to the inferior leads is highly sensitive and specific for pacing-induced TWIs rather than ischemia.<sup>4</sup>

At the time of evaluation in the electrophysiology clinic, he had undergone an extensive workup for ischemia, including coronary angiography. Because of recurrent, symptomatic palpitations, he underwent electrophysiology study with possible catheter ablation. He was found to have inducible orthodromic reentrant tachycardia via a midseptal bypass tract. He underwent successful radiofrequency catheter ablation with the elimination of his preexcitation and inducible tachycardia. His postablation ECG (Figure 2B) shows multiple leads with changes in T-wave amplitude and direction, most notably TWIs in leads III and aVF. At his follow-up visit, 2 months after ablation, his ECG continued to show the absence of preexcitation; however, the TWIs had resolved (Figure 2C), confirming the suspected diagnosis of cardiac memory.

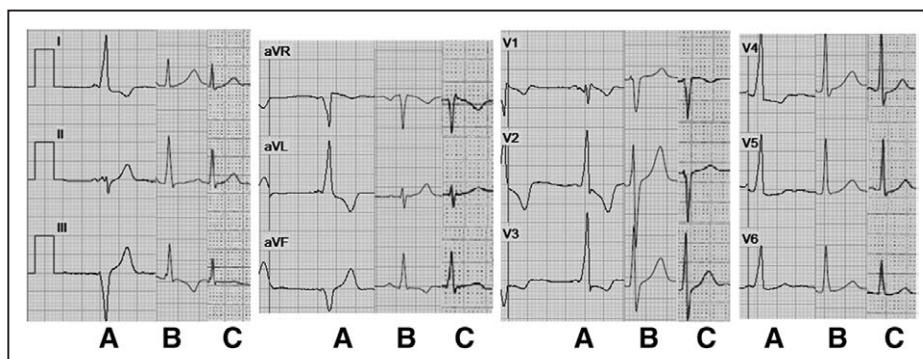
Cardiac memory can be seen in numerous contexts and should be considered in the setting of unexplained TWIs with an abrupt change from wide to narrow QRS complex. Most important, it should be recognized as a benign condition that will resolve over time rather than a marker of ischemia, infarction, or other pathological clinical conditions. In this case, the patient's chest pain remained unexplained, although he did report resolution of this symptom after catheter ablation of his accessory bypass tract.

## DISCLOSURES

None.

## AFFILIATIONS

From Division of Cardiology, Department of Medicine, Northwestern University, Feinberg School of Medicine, Chicago, IL.



**Figure 2.** Three 12-lead electrocardiograms depict cardiac memory after a midseptal bypass tract ablation.

**A**, Baseline (preablation) electrocardiogram (ECG) showing preexcitation. **B**, ECG obtained 1 hour after ablation. Multiple T-wave changes are shown, including T-wave inversions, flattening in the inferior leads, and normalization of the T-waves in the lateral leads and across the precordium. Note the tall, peaked T-waves in the right precordial leads. **C**, ECG obtained 2 months after ablation showing normalization of the inferior T-wave changes and a reduction in the amplitude of the right precordial T-waves.

---

## FOOTNOTES

*Circulation* is available at <http://circ.ahajournals.org>.

---

## REFERENCES

1. Nirei T, Kasanuki H, Ohnishi S, Tamaki A, Toyoshima Y, Hosoda S. Cardiac memory in patients with intermittent Wolff-Parkinson-White syndrome. *J Electrocardiol*. 1997;30:323–329.
2. Rosenbaum MB, Blanco HH, Elizari MV, Lázari JO, Davidenko JM. Electrotonic modulation of the T wave and cardiac memory. *Am J Cardiol*. 1982;50:213–222.
3. Chatterjee K, Harris A, Davies G, Leatham A. Electrocardiographic changes subsequent to artificial ventricular depolarization. *Br Heart J*. 1969;31:770–779.
4. Shvilkin A, Ho KK, Rosen MR, Josephson ME. T-vector direction differentiates postpacing from ischemic T-wave inversion in pre-cordial leads. *Circulation*. 2005;111:969–974. doi: 10.1161/01.CIR.0000156463.51021.07.

## Chest Pain and T-Wave Inversions in a 56-Year-Old Man

Nishant Verma and Bradley P. Knight

*Circulation*. 2017;135:998-1000

doi: 10.1161/CIRCULATIONAHA.117.027259

*Circulation* is published by the American Heart Association, 7272 Greenville Avenue, Dallas, TX 75231

Copyright © 2017 American Heart Association, Inc. All rights reserved.

Print ISSN: 0009-7322. Online ISSN: 1524-4539

The online version of this article, along with updated information and services, is located on the World Wide Web at:

<http://circ.ahajournals.org/content/135/10/998>

**Permissions:** Requests for permissions to reproduce figures, tables, or portions of articles originally published in *Circulation* can be obtained via RightsLink, a service of the Copyright Clearance Center, not the Editorial Office. Once the online version of the published article for which permission is being requested is located, click Request Permissions in the middle column of the Web page under Services. Further information about this process is available in the [Permissions and Rights Question and Answer](#) document.

**Reprints:** Information about reprints can be found online at:  
<http://www.lww.com/reprints>

**Subscriptions:** Information about subscribing to *Circulation* is online at:  
<http://circ.ahajournals.org/subscriptions/>