

Detection of Internal Thoracic Artery Dissection at Coronary Anastomosis Using Intraoperative 15-MHz High-Frequency Epicardial Ultrasound

Taiju Watanabe, MD; Hirokuni Arai, MD, PhD; Keiji Oi, MD, PhD;
Tsuyoshi Hachimaru, MD; Hidehito Kuroki, MD; Tatsuki Fujiwara, MD; Tomohiro Mizuno, MD, PhD

A 66-year-old man with a history of diabetes mellitus presented with angina pectoris with 3-vessel disease, and he underwent off-pump coronary artery bypass grafting via median sternotomy. After performing bypass grafting of the left internal thoracic artery to the left anterior descending artery, the appearance of anastomosis configuration appeared to be acceptable. However, transit time flow measurement (TTFM) showed that the mean graft flow was 10 mL/min, which was less than expected despite an acceptable flow curve with a diastolic flow pattern, a pulsatility index (index of resistance) of 2.0, and diastolic filling (proportion of diastole with coronary flow) of 65% (Figure 1). In addition to TTFM, the anastomosis was evaluated by using 15-MHz high-frequency epicardial ultrasound (VeriQ C system; Medistim, Oslo, Norway). It accurately detected an intimal flap of the left internal thoracic artery at the anastomosis site, and the restricted flow pattern in the true lumen was visualized by using Doppler color flow mapping (Figure 2; Movie I in the online-only Data Supplement). The anastomosis was successfully revised, with the use of TTFM to confirm an adequate flow value of 36 mL/min (Figure 3) and epicardial ultrasound to confirm a good configuration of the anastomosis.

There is growing concern regarding the increased risk of errors in anastomosis construction during off-pump coronary artery bypass grafting because the suturing process is technically more demanding than that in surgery on the arrested heart. The European Society of Cardiology/European

Association for Cardio-Thoracic Surgery guidelines on myocardial revascularization recently recommended intraoperative graft evaluation using TTFM.¹ However, graft flow measurement can only detect severe stenosis (>75%) and provides no information regarding anastomosis configuration; thus, the number of suboptimal anastomoses may be underestimated. In recent years, we introduced an approach using 15-MHz high-frequency epicardial ultrasound to increase diagnostic accuracy relative to that of using TTFM alone. In this case, high-frequency epicardial ultrasound demonstrated its ability to detect an anastomosis error that was not identified by TTFM alone. This approach can be used as a quality-control modality to provide information regarding graft function and anastomosis configuration.

Disclosures

None.

Reference

1. Task Force on Myocardial Revascularization of the European Society of Cardiology (ESC) and the European Association for Cardio-Thoracic Surgery (EACTS); European Association for Percutaneous Cardiovascular Interventions (EAPCI); Wijns W, Kolh P, Danchin N, Di Mario C, Falk V, Folliguet T, Garg S, Huber K, James S, Knuuti J, Lopez-Sendon J, Marco, Menicanti L, Ostojic M, Piepoli MF, Pirlet C, Pomar JL, Reifart N, Ribichini FL, Schalij MJ, Sergeant P, Serruys PW, Silber S, Sousa Uva M, Taggart D. Guidelines on myocardial revascularization. *Eur Heart J*. 2010;20:2501–2555.

From the Department of Cardiovascular Surgery, Tokyo Medical and Dental University Graduate School of Medical and Dental Sciences, Tokyo, Japan. The online-only Data Supplement is available with this article at <http://circ.ahajournals.org/lookup/suppl/doi:10.1161/CIRCULATIONAHA.114.008705/-/DC1>.

Correspondence to Hirokuni Arai, MD, PhD, The Department of Cardiovascular Surgery, Tokyo Medical and Dental University Graduate School of Medical and Dental Sciences, 1-5-45 Yushima Bunkyo-ku Tokyo, 113-8519, Japan. E-mail hiro.cvsg@tmd.ac.jp (*Circulation*. 2014;129:e513-e515.)

© 2014 American Heart Association, Inc.

Circulation is available at <http://circ.ahajournals.org>

DOI: 10.1161/CIRCULATIONAHA.114.008705

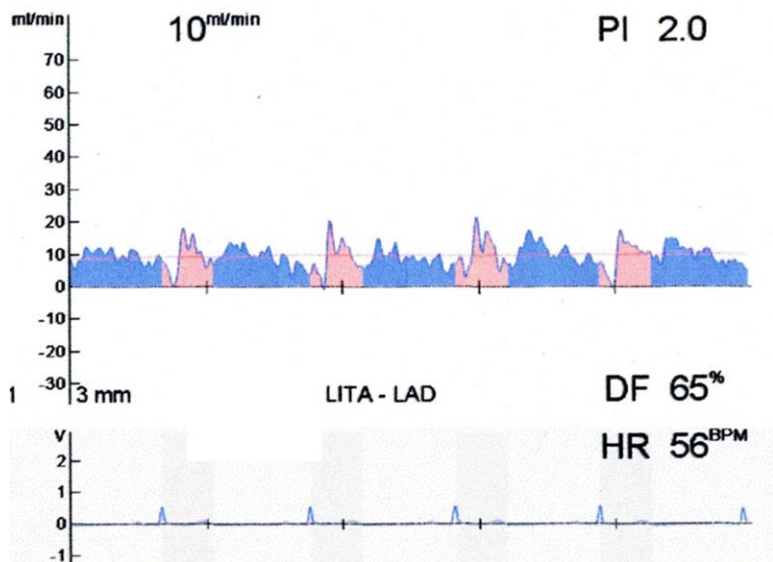


Figure 1. Intraoperative evaluation using transit-time flow measurement. After completion of the LITA-LAD anastomosis, transit time flow measurement showed that the mean graft flow was 10 mL/min, which was less than expected, although the PI and DF were acceptable. DF indicates diastolic filling; HR, heart rate; LAD, left anterior descending artery; LITA, left internal thoracic artery; and PI, pulsatility index.

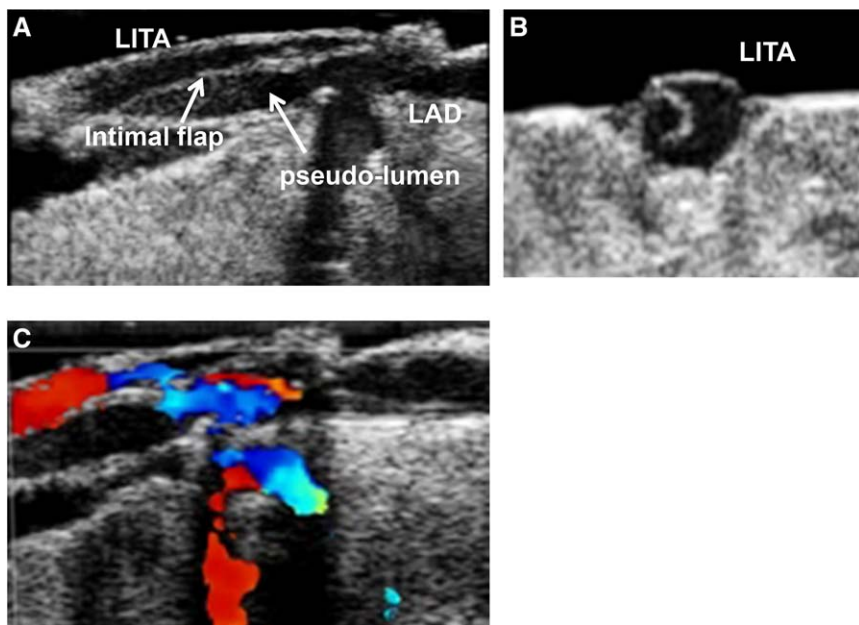


Figure 2. Intraoperative detection of an intimal flap of the LITA at the coronary anastomosis by using 15-MHz high-frequency epicardial ultrasound. **A**, Longitudinal view of the LITA-LAD anastomosis. **B**, Transverse view of dissection of the LITA. **C**, Doppler color flow mapping detected the restricted flow in the true lumen (longitudinal view). LAD indicates left anterior descending artery; and LITA, left internal thoracic artery;

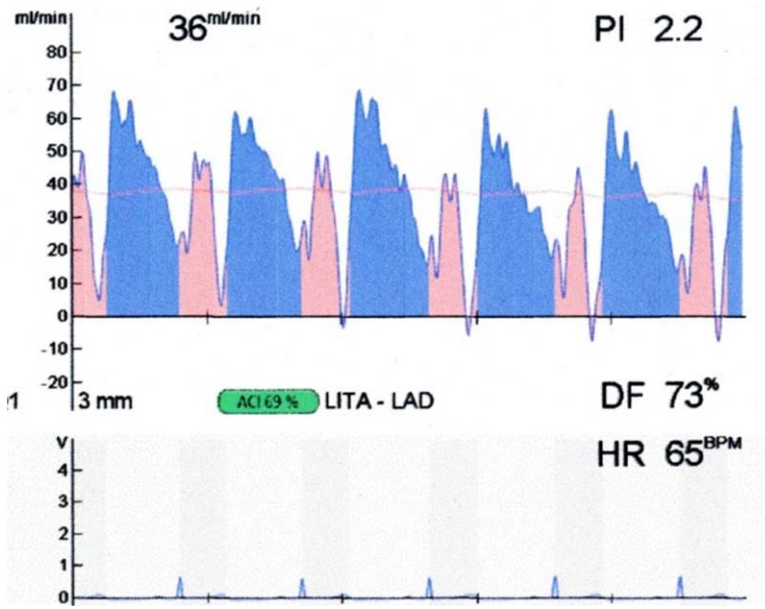


Figure 3. Intraoperative evaluation after the revision of the anastomosis by using transit time flow measurement. The anastomosis was successfully revised by using transit-time flow measurement to confirm an adequate flow value of 36 mL/min with acceptable flow pattern, pulsatility index, and diastolic filling. DF indicates diastolic filling; HR, heart rate; LAD, left anterior descending artery; LITA, left internal thoracic artery; and PI, pulsatility index.

**Detection of Internal Thoracic Artery Dissection at Coronary Anastomosis Using
Intraoperative 15-MHz High-Frequency Epicardial Ultrasound**
Taiju Watanabe, Hirokuni Arai, Keiji Oi, Tsuyoshi Hachimaru, Hidehito Kuroki, Tatsuki
Fujiwara and Tomohiro Mizuno

Circulation. 2014;129:e513-e515

doi: 10.1161/CIRCULATIONAHA.114.008705

Circulation is published by the American Heart Association, 7272 Greenville Avenue, Dallas, TX 75231

Copyright © 2014 American Heart Association, Inc. All rights reserved.

Print ISSN: 0009-7322. Online ISSN: 1524-4539

The online version of this article, along with updated information and services, is located on the
World Wide Web at:

<http://circ.ahajournals.org/content/129/22/e513>

Data Supplement (unedited) at:

<http://circ.ahajournals.org/content/suppl/2014/10/15/129.22.e513.DC1>

Permissions: Requests for permissions to reproduce figures, tables, or portions of articles originally published in *Circulation* can be obtained via RightsLink, a service of the Copyright Clearance Center, not the Editorial Office. Once the online version of the published article for which permission is being requested is located, click Request Permissions in the middle column of the Web page under Services. Further information about this process is available in the [Permissions and Rights Question and Answer](#) document.

Reprints: Information about reprints can be found online at:
<http://www.lww.com/reprints>

Subscriptions: Information about subscribing to *Circulation* is online at:
<http://circ.ahajournals.org/subscriptions/>