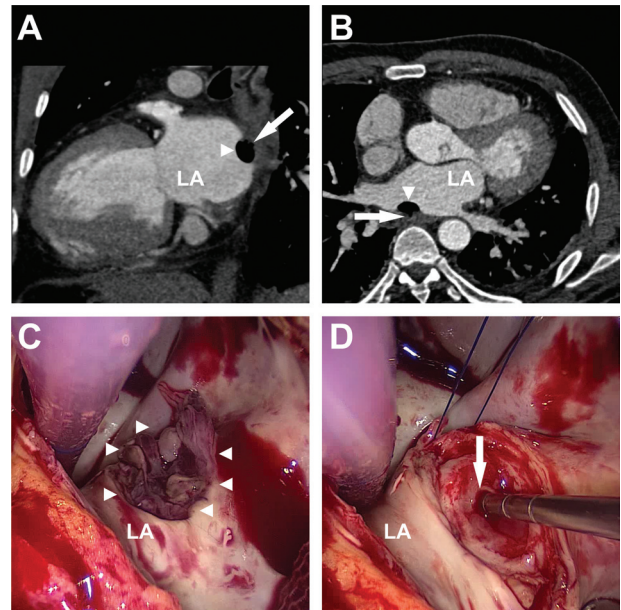


## Atrioesophageal Fistula After Percutaneous Transcatheter Ablation of Atrial Fibrillation

Ivan Tancevski, MD; Florian Hintringer, MD; Markus Stuehlinger, MD; Eva-Maria Gassner, MD; Nikolaos Bonaros, MD; Ludwig C. Mueller, MD; Johannes Mair, MD

A 45-year-old white man presented to the emergency department because of fever and fluctuating neurological symptoms including weakness and sensory loss of the right limbs. Six weeks before admittance, the patient had undergone percutaneous transcatheter ablation of drug-refractory atrial fibrillation. Laboratory examination showed markedly elevated white cell count and inflammatory markers, as well as moderately increased cardiac troponin T; however, no chest pain or gastrointestinal symptoms were reported, and the ECG was normal. Computed tomography (CT) scan of the chest revealed a fistula between the left atrium and the esophagus (Figure, A and B)<sup>1</sup>; the abdominal CT scan showed multiple renal and splenic infarctions. Subsequent cerebral magnetic resonance imaging revealed left temporoparietal and multifocal occipital ischemia and infarction. Together, these findings indicated diffuse embolic events. Intravenous antibiotic treatment with ampicillin/ceftriaxone was initiated, and neurological symptoms partially resolved over the next 48 hours. Subsequently, the patient underwent cardiac surgery, during which a 1.5-cm perforation of the posterior wall of the left atrium was found contiguous to myocardial necrosis (Figure, C) near the right lower pulmonary vein. Repair was accomplished with a 4×3-cm oval glutaraldehyde-fixed bovine pericardial patch. The esophageal fistula (Figure, D) was repaired with a direct suture. One week after operative repair, the atrioesophageal fistula (AEF) was reevaluated by CT scan of the chest, on which no extravasation of contrast from the esophagus was documented. The CT scan of the brain showed a significant reduction of cerebral damage. The patient survived without severe neurological deficits.

AEF is a rare but life-threatening complication of percutaneous catheter ablation,<sup>2</sup> with a mortality rate of 80%.<sup>3</sup> AEF after radiofrequency ablation for atrial fibrillation has a median time to appearance of 15 days,<sup>3</sup> and a long period of latency may hamper the diagnosis. However, if an AEF is suspected, CT scan of the chest is the recommended diagnostic tool because transesophageal echocardiography was reported to be detrimental.<sup>3</sup> Because most of the patients die of neurological complications, we suggest that empirical antimicrobial therapy with high blood-brain barrier permeability should be initiated immediately in individuals with suspected AEF.



**Figure.** Top, Computed tomography scans with intravenous contrast showing an air pocket (arrowhead) traversing the esophageal wall (arrow) and the posterior wall of the left atrium (LA), indicating a transmural fistulous tract (A, sagittal scan; B, axial scan). Bottom, Intraoperative photographs showing a 1.5-cm perforation of the posterior wall of the left atrium contiguous to myocardial necrosis (arrowheads) (C) and the esophageal fistula (arrow) (D), visible after removal of the necrotic tissue.

### Disclosures

None.

### References

1. Malamis AP, Kirshenbaum KJ, Nadimpalli S. CT radiographic findings: atrio-esophageal fistula after transcatheter percutaneous ablation of atrial fibrillation. *J Thorac Imaging*. 2007;22:188–191.
2. Cappato R, Calkins H, Chen SA, Davies W, Iesaka Y, Kalman J, Kim YH, Klein G, Natale A, Packer D, Skanes A. Prevalence and causes of fatal outcome in catheter ablation of atrial fibrillation. *J Am Coll Cardiol*. 2009;53:1798–1803.
3. Stollberger C, Pulgram T, Finsterer J. Neurological consequences of atrioesophageal fistula after radiofrequency ablation in atrial fibrillation. *Arch Neurol*. 2009;66:884–887.

From the Departments of Internal Medicine (I.T., F.H., M.S., J.M.), Radiology (E.G.), and Cardiac Surgery (N.B., L.C.M.), Innsbruck Medical University, Innsbruck, Austria.

Correspondence to Ivan Tancevski, MD, Department of Internal Medicine, Innsbruck Medical University, Anichstrasse 35, A-6020 Innsbruck, Austria. E-mail ivan.tancevski@i-med.ac.at

(*Circulation*. 2012;125:966.)

© 2012 American Heart Association, Inc.

*Circulation* is available at <http://circ.ahajournals.org>

DOI: 10.1161/CIRCULATIONAHA.111.044438

## Atrioesophageal Fistula After Percutaneous Transcatheter Ablation of Atrial Fibrillation

Ivan Tancevski, Florian Hintringer, Markus Stuehlinger, Eva-Maria Gassner, Nikolaos Bonaros, Ludwig C. Mueller and Johannes Mair

*Circulation*. 2012;125:966

doi: 10.1161/CIRCULATIONAHA.111.044438

*Circulation* is published by the American Heart Association, 7272 Greenville Avenue, Dallas, TX 75231

Copyright © 2012 American Heart Association, Inc. All rights reserved.

Print ISSN: 0009-7322. Online ISSN: 1524-4539

The online version of this article, along with updated information and services, is located on the World Wide Web at:

<http://circ.ahajournals.org/content/125/7/966>

**Permissions:** Requests for permissions to reproduce figures, tables, or portions of articles originally published in *Circulation* can be obtained via RightsLink, a service of the Copyright Clearance Center, not the Editorial Office. Once the online version of the published article for which permission is being requested is located, click Request Permissions in the middle column of the Web page under Services. Further information about this process is available in the [Permissions and Rights Question and Answer](#) document.

**Reprints:** Information about reprints can be found online at:  
<http://www.lww.com/reprints>

**Subscriptions:** Information about subscribing to *Circulation* is online at:  
<http://circ.ahajournals.org/subscriptions/>