

Atherosclerotic Peripheral Vascular Disease Symposium II Lower-Extremity Revascularization: State of the Art

Bruce H. Gray, DO, Chair; Michael S. Conte, MD; Michael D. Dake, MD;
Michael R. Jaff, DO, FAHA; Krishna Kandarpa, MD; Stephen R. Ramee, MD, FAHA;
John Rundback, MD, FAHA; Ronald Waksman, MD; for Writing Group 7

Percutaneous intervention for peripheral artery disease has evolved from balloon angioplasty for simple focal lesions to multimodality techniques that enable treatment of severe arterial insufficiency. This technological expansion comes without a standard approach or algorithm, which makes the decision-making process more subjective than objective. Nevertheless, clinical tools are available that can have a favorable effect on patient care, and these promote usage. So, when are standard endovascular techniques (such as balloon and stents) good enough, and when are the latest advances (eg, atherectomy, drug-eluting stents) more appropriate?

This section will address these questions for acute limb ischemia (ALI) and chronic critical limb ischemia (CLI). It will also delineate the problem of restenosis, particularly of the superficial femoral artery (SFA), and describe treatment alternatives. The discussion will review the role of drug-eluting stents, atherectomy devices, reentry catheters, and brachytherapy, as well as their potential complications and appropriate remedies. Treatment algorithms for aortoiliac and infrainguinal disease are provided in Figures 1 through 3.

Acute Limb Ischemia

ALI, defined as any sudden decrease or worsening in limb perfusion, is a threat to the limb of the young and to the life and limb of the elderly.¹ The severity of ALI and its probable cause should be determined emergently, because the time to diagnosis and initiation of treatment is inversely related to successful outcome. The amount of muscle mass jeopardized and the severity of ischemia are a function of the location and extent of the occlusion and the presence of collaterals around the acute obstruction.

Clinical categories of ALI, originally proposed and later modified by the Society for Vascular Surgery/International Society of Cardiovascular Surgeons, are useful for decision-making purposes (Figure 1).² On diagnosis, anticoagulation (to prevent thrombus propagation and/or embolization) and analgesia should be initiated, and any underlying medical comorbidities (eg, congestive heart failure) should be managed aggressively to stabilize the patient. The method used for direct revascularization must be tailored to the patient and to the skills (operative or endovascular) that are immediately available.

The options for prompt revascularization consist of (1) percutaneous catheter-directed thrombolytic therapy (CDTT), (2) percutaneous mechanical thrombus extraction with or without thrombolytic therapy, and (3) surgical thrombectomy or bypass. These treatments are complementary, each with advantages and limitations. In choosing a treatment, consideration should be given to location of the occlusion, type of occlusion (thrombus or embolus), duration of ischemia, patient-related risks, type of conduit (artery or graft), and therapy-related risks and outcomes.

Percutaneous CDTT

CDTT has evolved as the standard percutaneous approach for ALI because systemic infusions of thrombolytic agents were shown to have less safety and efficacy. Patients with limb-threatening ischemia (category I or II) and intact neurological function of the limb should undergo complete diagnostic imaging to assess the inflow and outflow of the arterial system. The ability of the operator to cross the occlusion with a guidewire (guidewire traversal test) determines the likelihood of success for CDTT. The results of the Surgery versus

The American Heart Association makes every effort to avoid any actual or potential conflicts of interest that may arise as a result of an outside relationship or a personal, professional, or business interest of a member of the writing panel. Specifically, all members of the writing group are required to complete and submit a Disclosure Questionnaire showing all such relationships that might be perceived as real or potential conflicts of interest.

The opinions expressed in this manuscript are those of the authors and are not necessarily those of the editors or the American Heart Association. The Executive Summary and other writing group reports for these proceedings are available online at <http://circ.ahajournals.org> (*Circulation*. 2008;118:2811–2825; 2826–2829; 2830–2836; 2837–2844; 2845–2851; 2852–2859; 2860–2863; and 2873–2878).

These proceedings were approved by the American Heart Association Science Advisory and Coordinating Committee on June 2, 2008. A copy of these proceedings is available at <http://www.americanheart.org/presenter.jhtml?identifier=3003999> by selecting either the “topic list” link or the “chronological list” link (No. LS-1882). To purchase additional reprints, call 843-216-2533 or e-mail kelle.ramsay@wolterskluwer.com.

Expert peer review of AHA Scientific Statements is conducted at the AHA National Center. For more on AHA statements and guidelines development, visit <http://www.americanheart.org/presenter.jhtml?identifier=3023366>.

Permissions: Multiple copies, modification, alteration, enhancement, and/or distribution of this document are not permitted without the express permission of the American Heart Association. Instructions for obtaining permission are located at <http://www.americanheart.org/presenter.jhtml?identifier=4431>. A link to the “Permission Request Form” appears on the right side of the page.

(*Circulation*. 2008;118:2864–2872.)

© 2008 American Heart Association, Inc.

Circulation is available at <http://circ.ahajournals.org>

DOI: 10.1161/CIRCULATIONAHA.108.191177

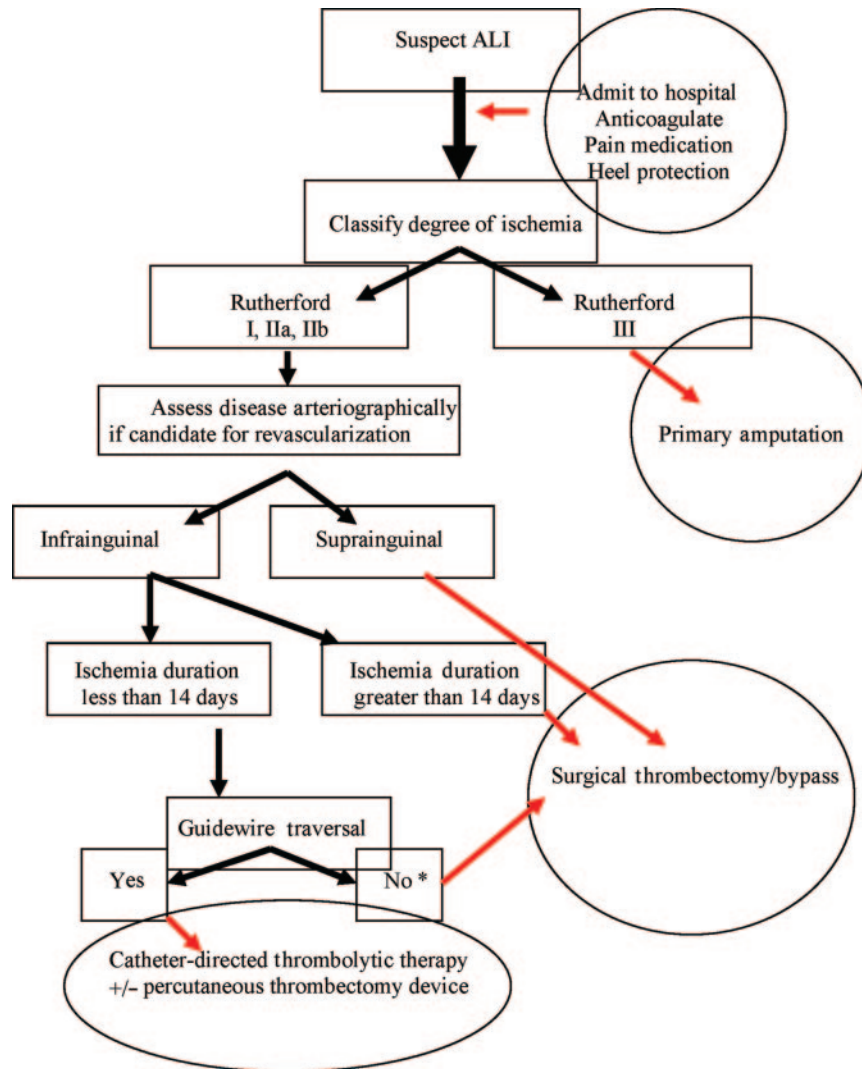


Figure 1. Treatment algorithm for acute lower-limb ischemia. *Short infusion of thrombolytic therapy proximal to occlusion can be used to facilitate wire traversal.

Thrombolysis for Ischemia of the Lower Extremity (STILE) Trial, which randomized patients with up to 6 months of ischemia, were significantly affected by the fact that 28% of the occlusions could not be crossed with a guidewire, which raised concerns about uniform operator skills. The study concluded that occlusions of <14 days' duration that could be crossed with a guidewire would undergo successful CDTT.³

On successful traversal, a multiside-hole catheter is placed that covers the entire length of the occlusion for delivery of the thrombolytic agent. A small bolus dose of the agent given through the catheter is helpful to initiate therapy. A power pulse-spray technique uses repeated high-pressure injections of the thrombolytic agent through the catheter. This technique can reestablish antegrade flow promptly but in general does not shorten the overall time for complete thrombus resolution because of residual adherent thrombus and potential distal embolization.

Studies comparing thrombolytic agents allow for several conclusions: (1) Urokinase is superior to streptokinase; (2) urokinase and tissue plasminogen activator show similar

efficacy, with a slightly higher bleeding risk with tissue plasminogen activator; and (3) reteplase and tenecteplase are as safe and efficacious as tissue plasminogen activator. Two new agents under study theoretically have some advantages. Alfimeprase, a direct fibrinolytic agent (not a plasminogen activator), acts on fibrin and fibrinogen. Once in the circulation, alfimeprase rapidly forms a complex with α -2 macroglobulin that is rapidly metabolized in the liver. This agent has the potential to cause rapid thrombolysis when delivered into the thrombus with minimal systemic effects, but unpublished initial clinical studies have failed to show acceptable efficacy. Intra-arterial infusion of plasmin, a direct fibrinolytic agent, by itself is also being investigated.

Concomitant infusion of anticoagulants and antiplatelet agents with thrombolytic agents has not been studied completely. No consensus exists on the use of heparin, bivalirudin, hirudin, or lepirudin during CDTT. Heparin minimizes the risk of pericatheter thrombus formation but increases the risk of access-site bleeding. Some operators use heparin to maintain a therapeutic activated partial thromboplastin time, whereas others use less than half the systemic doses or none.

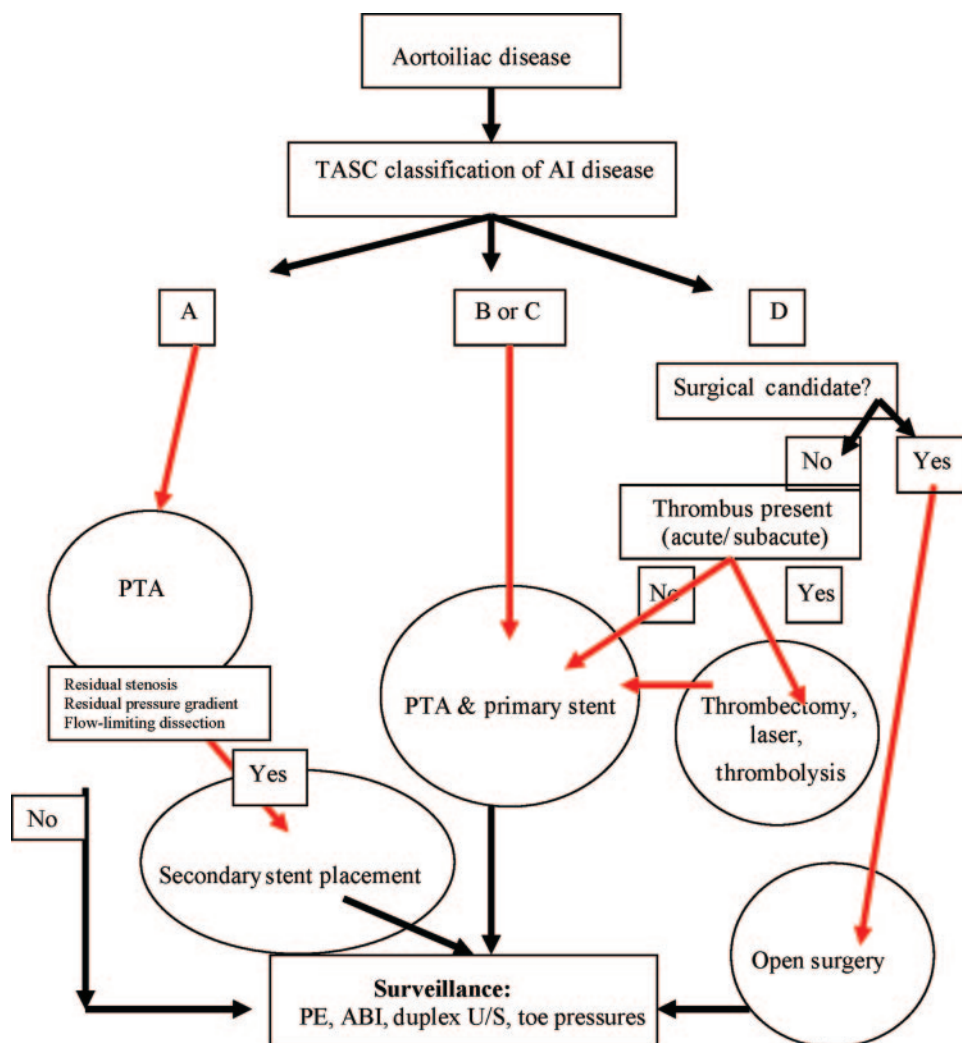


Figure 2. Simplified treatment algorithm for symptomatic aortoiliac disease in patients deemed candidates for revascularization. In patients with multilevel disease, the aortoiliac segment should be addressed first. TASC indicates TransAtlantic Inter-Society Consensus; AI, aortoiliac; PTA, percutaneous transluminal angioplasty; PE, physical examination; ABI, ankle-brachial index; and U/S, ultrasound.

The use of concomitant adjunctive antiplatelet agents such as abciximab, a monoclonal antibody against the glycoprotein IIb/IIIa platelet receptor, appears to shorten treatment time and embolization risk but is associated with an increased risk of bleeding. In general, a short-acting anticoagulant (“lower dose”) can be used with a thrombolytic agent, but full-dose anticoagulant or intravenous antiplatelet agents should be avoided.

Percutaneous Mechanical Thrombus Extraction

Several percutaneous thrombectomy devices are available. In general, percutaneous thrombectomy devices decrease the thrombus burden before CDTT; rapidly reestablish antegrade flow, particularly in synthetic bypass grafts compared with native arteries; remove thrombi better than emboli; can uncover underlying disease; and occasionally remove enough fresh thrombus to function as a stand-alone procedure.⁴ Clinical complications that are unique to percutaneous thrombectomy devices include hemolysis, which causes hematuria and anemia; rhabdomyolysis with renal failure; pancreatitis;

and vasospasm. The cost-benefit ratio for the percutaneous thrombectomy device over CDTT has not been evaluated fully. Selective rather than universal use of percutaneous thrombectomy devices is deemed prudent until the cost of the catheter and console can be justified relative to the total cost of prolonged (overnight) CDTT.

Surgical Thrombectomy or Bypass

Three prospective randomized trials have evaluated the roles of CDTT and surgical revascularization in patients with ALI.^{3,5,6} The Rochester Trial, a single-center study of 114 patients with ischemia of ≤ 7 days’ duration, reported equal 1-year limb-salvage rates of 82%, but the 1-year cumulative survival rate among thrombolytic therapy patients was significantly better than with surgical revascularization (84% versus 58%, respectively) because they experienced fewer in-hospital cardiopulmonary complications.⁵ The STILE Trial of 393 patients with ischemia of ≤ 6 months’ duration was terminated prematurely because recurrent ongoing ischemia at 1 month was significantly higher in the thrombolytic

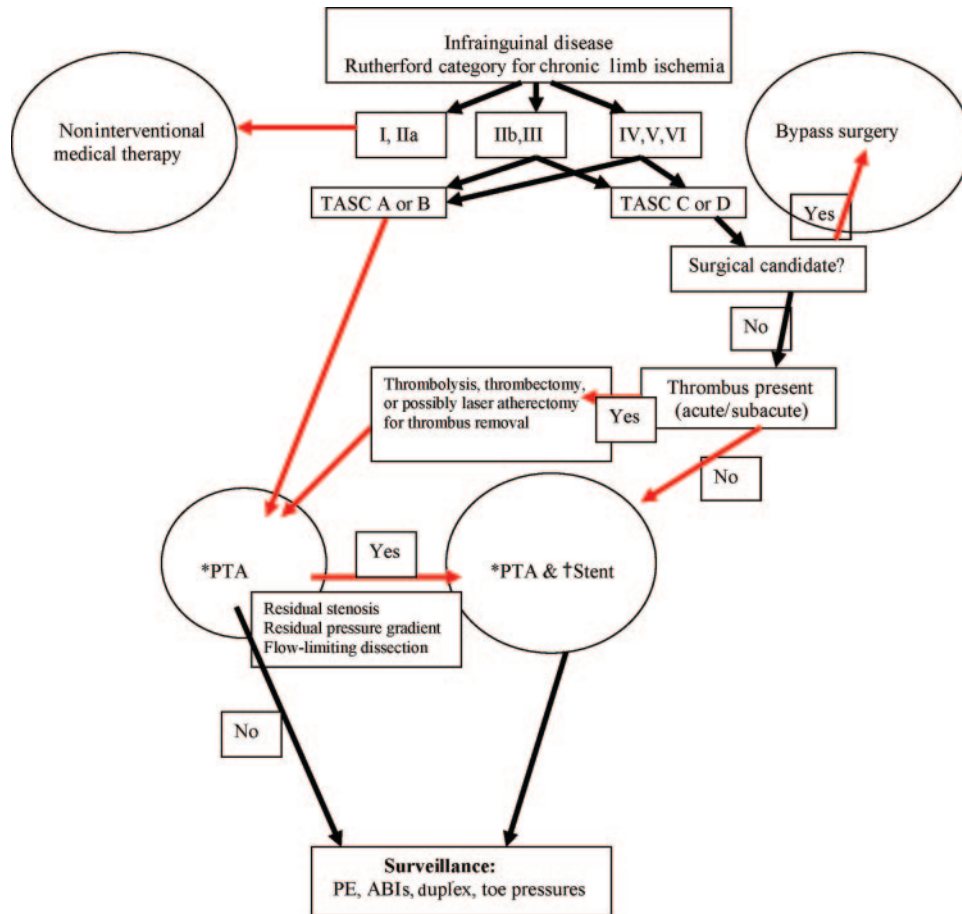


Figure 3. Simplified treatment algorithm for symptomatic infrainguinal peripheral arterial disease, assuming concomitant aortoiliac disease has been treated and the patient is an acceptable candidate for revascularization. *Alternative therapies to PTA include cryotherapy, atherectomy (directional, rotational, ablative), and cutting balloon. †Alternative stent options include stent (graft, balloon expanding, and self expanding) and drug-eluting stent. PTA indicates percutaneous transluminal angioplasty; TASC, TransAtlantic Inter-Society Consensus; PE, physical examination; ABI, ankle-brachial index; and U/S, ultrasound.

therapy group than in the group that underwent surgical revascularization (54% versus 26%, respectively).⁴ Nevertheless, a post hoc analysis stratified patients into 2 groups with ischemia duration of either ≤ 14 days (acute) or > 14 days (chronic). Patients with acute ischemia treated with thrombolytic therapy had a significantly better 6-month amputation-free survival rate and shorter hospital stays, whereas patients with chronic ischemia did better with surgical revascularization. The Thrombolysis Or Peripheral Arterial Surgery (TOPAS) Trial was a multicenter study that randomized 198 patients with ischemia duration of ≤ 14 days.⁶ There was no difference in 1-year amputation-free survival rates between thrombolytic therapy and surgical revascularization; however, thrombolytic therapy patients had a significantly reduced need for a surgical procedure.

Initial thrombolytic therapy is recommended for patients who have ischemia of ≤ 14 days' duration or graft occlusions, and initial surgical revascularization is recommended for those with ischemia of > 14 days' duration or native arterial occlusions. Thus, conduit type and age, duration of occlusion, and availability of vein for bypass should govern treatment. Early graft failure (< 6 months) is usually due to poor selection, a surgical technical error, or coagulopathy;

intermediate-term failure (6 to 18 months) is often due to intimal hyperplasia at the anastomoses; and long-term failure (> 18 months) is usually due to progression of atherosclerosis in the inflow or outflow vessels. The conduit material of choice for a graft is autogenous vein, because the long-term patency rates are far superior to those of prosthetic grafts (which now are usually only placed if vein is not available). Although prosthetic grafts may be treated successfully with CDTT, some surgeons prefer thrombectomy (with patch angioplasty at anastomoses) or replacement, as long as the limb is free of inflow or outflow lesions that can cause graft failure.

Several issues should be considered for future investigation of ALI. These include the following: (1) the relationship between the duration, severity, and extent of ischemia and the time available for successful treatment; (2) objective markers for determining severity of ischemia to better triage patients to appropriate and timely therapy; (3) prevention of reperfusion injury in limbs; and (4) quality-of-life assessment relative to catheter-based and surgical treatment.

Chronic CLI

CLI is usually caused by multilevel atherosclerotic disease, typically in patients with a history of cigarette smoking,

diabetes mellitus, or both. The risk of limb loss varies from 10% to 40% over the first year, with fewer than 50% of patients alive at 5 years.⁷ These patients die of cardiovascular disease, and therefore, evaluation must consider the systemic nature of the problem. Any treatment given for limb ischemia must take into account the comorbid conditions of the patient, with the appropriate application of medical, endovascular, and surgical therapies. In general, medical treatment of CLI carries the highest risk of limb loss; endovascular treatment carries low rates of morbidity and mortality but offers less durability than surgery; and surgical bypass improves durability with a higher short-term risk and cost. These treatments may be combined for effective care and should be viewed as complementary and not mutually exclusive.

Medical Therapies for CLI

Patients with CLI require aggressive evaluation of their cardiac, cerebrovascular, and renal status. Approximately one third of these patients will have severe coronary artery disease, renal artery stenosis, and carotid atherosclerosis. The systemic nature of the disease process requires risk evaluation, secondary risk factor modification, antiplatelet therapy, and regularly scheduled postrevascularization surveillance of these conditions.

The evidence available to support medical therapy for treatment of CLI is limited. Noninvasive therapies that may be tried for CLI include hyperbaric oxygen, prostaglandin infusion, intermittent pneumatic compression devices, and topical treatments ranging from growth factors to synthetic skin. These modalities should be considered ancillary to direct revascularization procedures.⁸

Endovascular Therapies for CLI

CLI has been a strong indication for surgical revascularization because patients typically have multilevel occlusive disease. The durability of bypass versus endarterectomy or endovascular procedures has affected the decision-making process to date. Many patients with CLI do not live long, however; they require improved circulation for only a shorter, finite period for wound healing and have limited medical reserve to undergo a major operation, which makes endovascular revascularization techniques attractive.

The Bypass versus Angioplasty in Severe Ischemia of the Leg (BASIL) Trial randomized 452 CLI patients to bypass surgery or angioplasty treatment first, with crossover allowed in the event of failure.⁹ These patients were preselected as candidates for either therapy and constituted only 30% of the entire CLI population. The immediate failure rates were 3% for surgery and 20% for angioplasty ($P<0.05$), with 1-year reintervention rates of 17% for surgery and 28% for angioplasty ($P<0.05$). The primary end point of amputation-free survival did not differ between treatment groups (56% with surgery first versus 50% with angioplasty first) at 1 year. Beyond 2 years, amputation-free survival and total survival rates were greater with surgery than with angioplasty. Quality of life did not differ between groups. The overall cost of care was less for the angioplasty-first strategy. To some practitioners, the improved durability of bypass proved that despite increased cost and short-term morbidity, bypass should be the

Table. Outcome Data Summarized by the TASC Document for 1-Year Morbidity/Mortality of Surgical Bypass and Interventional Procedures⁸

	Surgical Procedure	Endovascular Procedure
Mean time to heal foot ulceration, wk	15–20	Unknown
Incisional wound complication, %	15–25	8–15 (Access site)
Persistent severe lymphedema, %	10–20	0
Graft stenosis/percutaneous transluminal angioplasty restenosis, %	20	10–60 (Iliac-tibial)
Graft/percutaneous transluminal angioplasty occlusion, %	10–20	10–30
Need for graft surveillance studies, %	100	100
Major amputation, %	5–10	5–10
Death (perioperative/postoperative), %	2/10	0/17

first procedure offered to patients with CLI. Others support the main conclusion of the study that angioplasty is cheaper and less invasive, thus reserving surgical bypass for angioplasty failures or when angioplasty is not feasible, as discussed below.

Surgical Therapies for CLI

Not all patients with CLI should undergo revascularization. Patients with extensive necrosis or infectious gangrene and those who are nonambulatory may best be served with primary amputation. Ambulatory patients with long occlusions or heavily calcified arteries who have adequate venous conduits are best served by surgical bypass. The PREVENT (PROject of Ex Vivo vein graft ENgineering via Transfection) III Study provides a contemporary summary of surgical bypass for CLI patients.¹⁰ A total of 1404 patients were randomized to bypass surgery with an oligonucleotide or placebo for the prevention of vein graft failure. There were no significant differences in outcomes between the treatment groups. Overall, at 30 days, the death rate was 2.7%, the graft occlusion rate was 5.2%, the amputation rate was 1.8%, and the overall major morbidity rate was 17.6%. Conventional surgical end points showed a primary patency rate of 60.4%, a secondary patency rate of 78.5%, a survival rate of 83.8%, and a limb-salvage rate of 88.4% at 1 year.¹⁰

Outcome data summarized by the Inter-Society Consensus (TASC) document for 1-year morbidity/mortality of surgical bypass and interventional procedures are reported in the Table.⁸ The outcome of revascularization procedures is affected by anatomic and clinical factors. The quality of the distal vessels (runoff), length of the treated segment/bypass, and number of levels of disease treated (aortoiliac, femoral, tibial) influence outcomes. Patient-specific factors such as persistent smoking, diabetes mellitus, renal failure, and cardiac dysfunction negatively affect outcomes. Combination procedures can take advantage of the strengths offered by

each technique. For example, balloon angioplasty with stenting of an iliac occlusion followed by bypass of a long SFA occlusion combines the advantages of each procedure and minimizes the risk to the patient to achieve resolution of CLI.

The best procedure is the one that is specifically tailored to the individual patient, with minimization of physician bias. Percutaneous and open surgical procedures need to be available and used in a complementary fashion.

SFA Disease

Novel Treatment Therapies

Diseased SFAs possess unique characteristics and challenges for endovascular intervention in patients with CLI. Occlusions predominate; calcification is common; compressive and torsional forces break stiff, self-expanding nitinol stents; external compression collapses balloon-expandable stents; and aggressive intimal hyperplasia occurs not infrequently after intervention. Other challenges include limited technical success, increased use of resources (eg, time, equipment, money), prolonged radiation exposure from long procedural times, and high complication rates. Catheter and wire alternatives have been developed to maximize technical success by facilitating lesion traversal and direct lesion treatment.

Catheter and Wire Advancements to Facilitate Lesion Traversal

Hydrophilic coated wires have radically changed the ability to traverse lesions. These wires, with catheter support, can be used to cross through the true lumen or to create a subintimal channel. The 0.035-inch hydrophilic wire has the body and pushability to meet the demand of most SFA occlusions. Smaller 0.014-inch hydrophilic wires have become popular for some interventionalists who extrapolate coronary artery techniques into the periphery. Alternative strategies include the use of laser light (Spectranetics, Colorado Springs, Colo), which disrupts the fibrous cap of the occlusion and then ablates thrombus and plaque, allowing wire passage. Laser use can shorten traversal time, decrease thrombus burden in the occluded segment, and minimize the risk of embolization after obligatory percutaneous transluminal angioplasty.¹¹ Still, its use is limited by its cost and the absence of long-term efficacy data. The use of a dissecting catheter (Frontrunner, Cordis, Miami, Fla) can also break the fibrous cap of a proximal occlusion and cross a lesion. A proximal occlusion stump is helpful to start the dissection in the proper plane with this catheter. Once across the occlusion, it is removed before wire traversal. The CROSSER system (FlowCardia, Inc, Sunnyvale, Calif) uses vibration (20 000 cycles per second) at the tip of a catheter to “jackhammer” through an occlusion. Preliminary data in the Peripheral Approach To Recanalization In Occluded Totals (PATRIOT) trial of 40 patients showed success in the majority of cases.¹²

Reentry catheters are used to return to the arterial lumen from the subintimal plane at the distal occlusion. This avoids further extension of the subintimal plane distally, which can disrupt important collaterals. Reentry is made with a curved needle extruded back into the lumen, through which a 0.014-inch guidewire is passed. This needle extrusion is performed with biplane imaging to orient the catheter mark-

ers in the right direction (Outback, Cordis) or with intravascular ultrasound guidance (Medtronic Pioneer, Minneapolis, Minn). Once across the lesion, treatment options are variable.

Catheter Options for Lesion Treatment

Multiple strategies have been used to improve the long-term durability of SFA treatment. Balloon angioplasty remains the standard, with bare nitinol stents used in either a primary or secondary strategy. Atherectomy (rotational, directional, or ablative) has been used with variable frequency and results.^{13–15} Removal of plaque with these devices appears attractive; however, incomplete plaque removal, an inability to control the depth of atherectomy, and distal embolization have limited their use. No prospective, randomized data exist to support routine debulking before angioplasty.

Advancements in bare nitinol stent technology, particularly those with axial flexibility to resist fracture, may improve outcomes. Comparative data are still limited and are insufficient to discriminate among nitinol stents. Covered stents (nitinol with polytetrafluoroethylene or expanded polytetrafluoroethylene) cover long-segment disease well and provide excellent angiographic and short-term clinical results. They have a propensity to thrombosis and require indefinite maintenance with anticoagulant or antiplatelet agents. Stent stenosis may predispose to occlusion and must be monitored with duplex ultrasound. Advancements with drug-eluting and bioabsorbable stents are discussed below. Unfortunately, it is not currently possible to use any anatomic or patient criteria to accurately predict which diseased segments and affected individuals are the most amenable to obtaining a technically successful and clinically durable recanalization procedure.

Drug-Eluting Stents

Restenosis after endovascular therapy for infrainguinal peripheral arterial disease remains a major obstacle to widespread adoption as primary treatment of symptomatic peripheral arterial disease. With the dramatic improvement in restenosis rates realized in large-scale prospective, multicenter, randomized trials in coronary artery disease using drug-eluting stents compared with bare-metal stents, it seems intuitive that similar technology would result in clinical and anatomic benefits in infrainguinal peripheral arterial disease. Unfortunately, data evaluating such therapy are limited.

Two publications exist that evaluated drug-eluting stents compared with bare-metal stents in the SFA.^{16,17} SIROCCO 1 (SIROLimus Coated Cordis S.M.A.R.T. Nitinol Self-expandable Stent for the Treatment of Obstructive superficial femoral artery disease) compared sirolimus-coated, self-expanding nitinol stents (Cordis Endovascular, Warren, NJ) with identical nitinol self-expanding stents without the drug coating or polymer in 36 patients in Europe and Canada.¹⁶ Sirolimus is the same drug used on coronary artery stents. All patients were symptomatic and diagnosed as Rutherford class 2, 3, or 4. SFA lesions were 4 to 20 cm in length, either stenosis (>70%) or occlusion. All patients underwent 6-month posttreatment contrast arteriography, which led to the primary end point of in-stent mean percent diameter stenosis as determined by quantitative angiography.

The 2 patient cohorts had similar clinical and anatomic characteristics, with the sole exception of greater evidence of calcification of the SFA lesion in the drug-eluting stent group (100%, versus 46.7% in the bare-metal stent group; $P=0.002$). Mean SFA lesion length was 85 mm, and the mean number of stents implanted was 2.2 per patient. At the 6-month end point, the mean percent diameter stenosis was $22.6\pm 16.5\%$ in the drug-eluting stent cohort, compared with $30.9\pm 27.2\%$ in the bare-metal stent group. There was no significant difference between groups. No occlusions were seen in the drug-eluting stent group, and only 1 (5.9%) was seen in the bare-metal stent group. No patient required a secondary revascularization procedure at 6 months. Of note, 6 stent fractures occurred in the trial, 3 in each arm. No patient with a stent fracture experienced an adverse event or required revascularization as a result of the fracture.

SIROCCO 2 expanded the treatable population and limited the lesion lengths so that all lesions could be covered by no more than 2 stents.¹⁷ Fifty-seven patients with Rutherford 2, 3, or 4 symptoms were included. SFA lesions were limited to 7- to 14.5-cm stenosis length or 4- to 14.5-cm occlusion length. Of the eligible cohort, 29 received the sirolimus-coated S.M.A.R.T. stent, whereas 28 received the bare S.M.A.R.T. stent. Once again, the primary end point was in-stent mean lumen diameter at 6 months by quantitative angiography.

In SIROCCO 2, the mean lesion length was 81.5 mm, somewhat shorter than that seen in SIROCCO 1. As in SIROCCO 1, the primary end point demonstrated no significant difference: The mean lumen diameters were 4.94 ± 0.69 mm in the drug-eluting stent group and 4.76 ± 0.54 mm in the bare-metal stent group. Four stent fractures were identified in SIROCCO 2 at 6 months—2 in each arm of the trial. No clinical adverse events occurred in the 4 patients with stent fractures.

These 2 feasibility studies suggest that drug-eluting stents do not offer benefit in SFA disease, in contrast to the favorable outcomes shown in coronary artery disease. The concentration of sirolimus placed on the nitinol self-expanding stents in the SIROCCO series was not well controlled, which made it difficult to determine which, if any, stent had the appropriate dose. Of note, the patients who received sirolimus with a longer elution platform did do better than those with the shorter elution platform. In addition, because the pathophysiology of SFA disease is vastly different from the coronary artery, it is uncertain whether the drug actually reached the target cell. Finally, the use of a “top coat” or covering over the active pharmaceutical agent, which theoretically allows for delayed drug release, as was done in the SIROCCO trials, remains an unclear variable in drug-eluting technology for SFA disease. There is an ongoing clinical trial in the United States, the Zilver-PTX trial (Cook, Inc, Bloomington, Ind) in which paclitaxel, which has been shown to dramatically reduce coronary artery in-stent restenosis, has been placed on the surface of nitinol self-expanding stents, although without a top coat. This randomized, prospective, multicenter trial comparing a drug-eluting stent with a bare-metal stent has completed its feasibility phase and is now enrolling patients in the pivotal segment of the trial.

Treatment of SFA In-Stent Restenosis

Recent advances in catheter and stent technology have failed to solve the problem of SFA restenosis. Studies have shown the incidence of in-stent restenosis increases with the length of the treated lesion (ie, stent). Restenosis rates vary according to the imaging modality used. Duplex ultrasound shows an in-stent restenosis rate of 36.7%, compared with an angiographic restenosis rate of 20% to 25% at 12 months.¹⁸

In-stent restenosis occurs because of neointimal hyperplasia, because intact stents limit elastic recoil. Stents stretch the artery more than balloon angioplasty, which predisposes them to neointimal formation, but the overall luminal gain is maintained by limiting recoil. Stent fracture can cause mechanical restenosis through loss of the radial strength of the stent.

Endovascular treatment for in-stent restenosis includes balloon angioplasty, cutting balloon angioplasty, bare-metal stent, stent grafts, sonotherapy, cryotherapy, vascular brachytherapy, and laser/directional/rotational atherectomy. Two treatment strategies have shown efficacy for coronary in-stent restenosis (drug-eluting stents and vascular brachytherapy), but there is no consensus for the treatment of SFA in-stent restenosis.

The attractiveness of drug-eluting stents was discussed in the previous section. For in-stent restenosis, drug-eluting stents may not avoid the complication of late thrombosis, subsequent stent fracture, and reocclusion. Further studies with drug-eluting stents for SFA restenosis are warranted. Anecdotes have been reported about the efficacy of covered stents (ie, polytetrafluoroethylene-covered nitinol stents), but no data exist to suggest that these will provide a breakthrough. “Edge stenosis” and acute thrombotic tendencies may limit their overall utility for this disease.

Vascular brachytherapy is the only approved therapy for in-stent restenosis of bare-metal stents in coronary arteries. Will it also work for SFA in-stent restenosis? Three studies (Vienna 2, Vienna 4, and Peripheral Artery Radiation Investigational Study [PARIS]) provide some data showing patency rates of 80% for SFA in-stent restenosis at 6 months.¹⁹ Nevertheless, late restenosis or catch-up occurs by 3 years of follow-up, which suggests that brachytherapy merely delays restenosis. Technical limitations include the lack of an SFA-specific centering catheter, convenient γ -radiation-delivery environment, and management of the access site in the radiation oncology suite. Furthermore, β -radiation has weak penetration and is limited to a 60-mm treatment length, so the use of the approved coronary system is impractical for most SFA lesions. Brachytherapy at the time of stenting should be avoided because of the escalated risk of acute thrombosis. External radiation can be used but predisposes to nerve and soft tissue injury.

Biodegradable stents are under study in Europe. Preliminary data show a restenosis rate of $\geq 20\%$ at 6 months, which suggests that drug elution may also be a necessary component to these stents if they are going to provide the solution to SFA restenosis.²⁰

Management of Access-Site Complications

Complications with percutaneous procedures occur most frequently at the access site, affecting 5% to 18% of proce-

dures.²¹ Lack of hemostasis after removal of the sheath is the most common problem. Contributing factors include patient characteristics (female sex, obesity, low body weight, and hypertension) and procedural factors such as sheath issues (prolonged sheath time, large arterial sheath, concomitant venous sheath, and repeat sheath insertion), the use of anticoagulants and antiplatelet agents, multiple arterial punctures (including Seldinger technique) or arterial calcification, inadequate external compression after the procedure (usually in the obese patient), guidewire perforation of the external iliac artery or branch, non-common femoral artery access site, and failure of a closure device.²²

The initial management of suspected bleeding from the groin must include hand pressure at the access site regardless of the presence of a hematoma, aggressive fluid resuscitation, and notification of medical personnel capable of direct treatment (endovascular or open) of the arteriotomy site. During the initial resuscitation of the patient, reevaluation of the puncture site is important. High punctures of the proximal common femoral artery or distal external iliac artery predispose to retroperitoneal hemorrhage. Access-site hematomas can usually be controlled and decompressed with external manual compression. It may be difficult to use external manual pressure to control high puncture sites, nonfemoral arterial sites, or a rapidly expanding hematoma, and these are likely to require prompt intervention. Unstable patients with persistent bleeding require both diagnostic and therapeutic intervention.

Most acute bleeds can be handled with endovascular techniques such as balloon tamponade or covered stents. The first line of intervention is dependent on physician expertise with endovascular or surgical treatment. Surgical exploration should be considered in the presence of tense hematomas that compromise skin integrity. Late complications, such as an infected groin hematoma or endarteritis causing recurrent bleeding, require surgical intervention. Persistent pseudoaneurysms can be treated with ultrasound-guided compression or direct thrombin injection.

Acute ischemia of a limb can occur from distal embolization or thrombosis of the access site or treatment site. When this occurs during the procedure, the arteriographic flow pattern becomes sluggish or stagnant. After the procedure, the diagnosis can be made reliably with physical examination and a handheld Doppler device. Medical therapy with aggressive anticoagulation or systemic thrombolysis will not be adequate in most cases. Arteriography should be performed promptly by use of a remote access site. Percutaneous intervention with balloon angioplasty, stents, thrombectomy devices, and catheter-directed thrombolytic agents can resolve ischemia rapidly. Balloon angioplasty is helpful to treat underlying disease once the offending thrombus is removed. Thrombus can be removed with a thrombectomy device or small doses of a directly delivered thrombolytic agent. Residual dissection flaps or resilient atherosclerotic plaque can be treated with a stent; however, when the lesion is in the common femoral artery, surgical endarterectomy is preferred to a stent. Surgical bypass, patch angioplasty, and Fogarty thrombectomy options should be available and used if endovascular techniques fail to resolve the ischemia.

Infrequent access-site complications such as nerve injury, arteriovenous fistula, lymphocele formation, or infected closure device (cellulitis) can be observed under medical treatment initially. Most resolve without intervention; however, surgical drainage is required for abscesses, which should be discriminated from simple cellulitis.

The importance of access-site care and maintenance cannot be underestimated, because patients often grade their “experience” on the basis of the visual evidence. Prophylactic efforts to minimize access-site complications include the use of fluoroscopy before needle cannulation of the common femoral artery, use of a single-wall puncture technique, commitment to standard sterile techniques throughout the case, administration of a single dose of antibiotic at the time of the procedure, selective use of pressure dressings after sheath removal, and requisite observation time before discharge.

Conclusions

The heterogeneity of peripheral artery disease poses a tremendous challenge to the design, enrollment, and analysis of device trials. Lack of randomized, controlled data limits the authoritative conclusion of consensus documents. Further investigations of catheter-based therapy are necessary, and these should include clinical end points in addition to arterial patency and limb salvage, such as short-term morbidity, long-term morbidity, procedural mortality, symptomatic improvement, limb salvage, quality of life, functional status, and overall cost of primary and secondary procedures. Armed with this information, physicians can make objective decisions, and patients can be properly advised before a procedure.

Disclosures

Potential conflicts of interest for members of the writing groups for all sections of these conference proceedings are provided in a disclosure table included with the Executive Summary, which is available online at <http://circ.ahajournals.org/cgi/reprint/118/25/2811>.

References

1. TASC Working Group. Management of peripheral arterial disease: Transatlantic Inter-Society Consensus (section C). *J Vasc Surg*. 2000;31:S135–S167.
2. Rutherford RB, Baker JD, Ernst C, Johnston KW, Porter JM, Ahn S, Jones DN. Recommended standards for reports dealing with lower extremity ischemia: revised version [published correction appears in *J Vasc Surg*. 2001;33:805]. *J Vasc Surg*. 1997;26:517–538.
3. The STILE Investigators. Results of a prospective randomized trial evaluating surgery versus thrombolysis for ischemia of the lower extremity: the STILE trial. *Ann Surg*. 1994;220:251–266.
4. Kasirajan K, Gray B, Beavers FP, Clair DG, Greenberg R, Mascha E, Ouriel K. Rheolytic thrombectomy in the management of acute and subacute limb-threatening ischemia. *J Vasc Interv Rad*. 2001;12:413–421.
5. Ouriel K, Shortell CK, De Weese JA, Green RM, Francis CW, Azodo MV, Gutierrez OH, Manzione JV, Cox C, Marder VJ. A comparison of thrombolytic therapy with operative revascularization in the initial treatment of acute peripheral arterial ischemia. *J Vasc Surg*. 1994;19:1021–1030.
6. Ouriel K, Veith FJ, Sasahara AA; Thrombolysis or Peripheral Arterial Surgery (TOPAS) Investigators. A comparison of recombinant urokinase with vascular surgery as an initial treatment for acute arterial occlusions of the leg. *N Engl J Med*. 1998;338:1105–1111.

7. Hirsch AT, Haskal ZI, Hertzner NR, Bakal CW, Creager MA, Halperin JL, Hiratzka LF, Murphy WR, Olin JW, Puschett JB, Rosenfield KA, Sacks D, Stanley JC, Taylor LM Jr, White CJ, White J, White RA, Antman EM, Smith SC Jr, Adams CD, Anderson JL, Faxon DP, Fuster V, Gibbons RJ, Hunt SA, Jacobs AK, Nishimura R, Ornato JP, Page RL, Riegel B. ACC/AHA 2005 guidelines for the management of patients with peripheral arterial disease (lower extremity, renal, mesenteric, and abdominal aortic): a collaborative report from the American Association for Vascular Surgery/Society for Vascular Medicine and Biology, Society of Interventional Radiology, and the ACC/AHA Task Force on Practice Guidelines (Writing Committee to Develop Guidelines for the Management of Patients With Peripheral Arterial Disease). *J Am Coll Cardiol*. 2006;47:1–192.
8. Norgren L, Hiatt WR, Dormandy JA, Nehler MR, Harris KA, Fowkes FG; TASC II Working Group, Bell K, Caporusso J, Durand-Zaleski I, Komori K, Lammer J, Liapis C, Novo S, Razavi M, Robbs J, Schaper N, Shigematsu H, Savoal M, White C, White J, Clement D, Creager M, Jaff M, Mohler E III, Rutherford RB, Sheehan P, Sillesen H, Rosenfield K. Inter-society consensus for the management of peripheral arterial disease (TASC II). *Eur J Vasc Endovasc Surg*. 2007;33:(suppl):S1–S75.
9. Adam DJ, Beard JD, Cleveland T, Bell J, Bradbury AW, Forbes JF, Fowkes FG, Gillespie I, Ruckley CV, Raab G, Storkey H; BASIL Trial Participants. Bypass versus Angioplasty in Severe Ischaemia of the Leg (BASIL): multicentre, randomised controlled trial. *Lancet*. 2005;366:1925–1934.
10. Conte MS, Bandyk DF, Clowes AW, Moneta GL, Seely L, Lorenz TJ, Namini H, Hamdan AD, Roddy SP, Belkin M, Bercili SA, DeMasi RJ, Samson RH, Bermann SS; PREVENT III Investigators. Results of PREVENT III: a multicenter, randomized trial of edifoligide for the prevention of vein graft failure in lower extremity bypass surgery. *J Vasc Surg*. 2006;43:742–751.
11. Laird JR, Zeller T, Gray BH, Scheinert D, Vranic M, Reiser C, Biaino G; LACI Investigators. Limb salvage following laser-assisted angioplasty for critical limb ischemia: results of the LACI multicenter trial. *J Endovasc Ther*. 2006;13:1–11.
12. Melzi G, Cosgrove J, Biondi-Zoccai GL, Airoldi F, Michev I, Chieffo A, Sangiorgi GM, Montorfano M, Carlino M, Colombo A. A novel approach to chronic total occlusions: the Crosser system. *Catheter Cardiovasc Interv*. 2006;68:29–35.
13. Zeller T, Rastan A, Sixt S, Schwarzwälder U, Schwarz T, Frank U, Bürgelin K, Müller C, Rothenpieler U, Flügel PC, Tepe G, Neumann FJ. Long-term results after directional atherectomy of femoro-popliteal lesions. *J Am Coll Cardiol*. 2006;48:1573–1578.
14. Mahmud E, Keramati S, Salami A, Palakodeti V, Tsimikas S. Expanded applications of rotational atherectomy in contemporary coronary and peripheral interventional practice. *J Invasive Cardiol*. 2005;17:207–210.
15. Zhou W, Bush RL, Lin PH, Peden EK, Lumsden AB. Laser atherectomy for lower extremity revascularization: an adjunctive endovascular treatment option. *Vasc Endovascular Surg*. 2006;40:268–274.
16. Duda SH, Pusich B, Richter G, Landwehr P, Oliva VL, Tielbeek A, Wiesinger B, Hak JB, Tielemans H, Ziemer G, Cristea E, Lansky A, Bérégi JP. Sirolimus-eluting stents for the treatment of obstructive superficial femoral artery disease: six-month results. *Circulation*. 2002;106:1505–1509.
17. Duda SH, Bosiers M, Lammer J, Scheinert D, Zeller T, Tielbeek A, Anderson J, Wiesinger B, Tepe G, Lansky A, Mudde C, Tielemans H, Bérégi JP. Sirolimus-eluting versus bare nitinol stent for obstructive superficial femoral artery disease: the SIROCCO II trial. *J Vasc Interv Radiol*. 2005;16:331–338.
18. Ubbink DT, Fidler M, Legemate DA. Interobserver variability in aortoiliac and femoropopliteal duplex scanning. *J Vasc Surg*. 2001;33:540–545.
19. Pokrajac B, Schmid R, Kirisits C, Mock U, Fellner C, Wambersie A, Potter R, Minar E. Possible impact of iridium-192 source centering on restenosis rate after femoro-popliteal angioplasty and endovascular brachytherapy in Vienna-2 study. *Radiother Oncol*. 2002;63:97–102.
20. Peeters P, Bosiers M, Verbist J, Deloose K, Heublein B. Preliminary results after application of absorbable metal stents in patients with critical limb ischemia. *J Endovasc Ther*. 2005;12:1–5.
21. Cox N, Resnic FS, Popma JJ, Simon DI, Eisenhauer AC, Rogers C. Comparison of the risk of vascular complications associated with femoral and radial access coronary catheterization procedures in obese versus nonobese patients. *Am J Cardiol*. 2004;94:1174–1177.
22. Michalis LK, Rees MR, Patsouras D, Katsouras CS, Goudevenos J, Pappas S, Sourla E, Kolettis T, Sioros L, Zotou P, Gartzou-Matsouka P, Sideris DA. A prospective randomized trial comparing the safety and efficacy of three commercially available closure devices (Angioseal, Vasoseal and Duett). *Cardiovasc Intervent Radiol*. 2002;25:423–429.

KEY WORDS: AHA Conference Proceedings ■ arteriosclerosis ■ peripheral vascular disease ■ revascularization ■ claudication

Atherosclerotic Peripheral Vascular Disease Symposium II: Lower-Extremity Revascularization: State of the Art

Bruce H. Gray, Michael S. Conte, Michael D. Dake, Michael R. Jaff, Krishna Kandarpa,
Stephen R. Ramee, John Rundback, Ronald Waksman and for Writing Group 7

Circulation. 2008;118:2864-2872

doi: 10.1161/CIRCULATIONAHA.108.191177

Circulation is published by the American Heart Association, 7272 Greenville Avenue, Dallas, TX 75231

Copyright © 2008 American Heart Association, Inc. All rights reserved.

Print ISSN: 0009-7322. Online ISSN: 1524-4539

The online version of this article, along with updated information and services, is located on the
World Wide Web at:

<http://circ.ahajournals.org/content/118/25/2864>

Permissions: Requests for permissions to reproduce figures, tables, or portions of articles originally published in *Circulation* can be obtained via RightsLink, a service of the Copyright Clearance Center, not the Editorial Office. Once the online version of the published article for which permission is being requested is located, click Request Permissions in the middle column of the Web page under Services. Further information about this process is available in the [Permissions and Rights Question and Answer](#) document.

Reprints: Information about reprints can be found online at:
<http://www.lww.com/reprints>

Subscriptions: Information about subscribing to *Circulation* is online at:
<http://circ.ahajournals.org/subscriptions/>