

Percutaneous and Minimally Invasive Valve Procedures A Scientific Statement From the American Heart Association Council on Cardiovascular Surgery and Anesthesia, Council on Clinical Cardiology, Functional Genomics and Translational Biology Interdisciplinary Working Group, and Quality of Care and Outcomes Research Interdisciplinary Working Group

Todd K. Rosengart, MD, FAHA, Chair; Ted Feldman, MD; Michael A. Borger, MD, PhD;
Thomas A. Vassiliades, Jr, MD; A. Marc Gillinov, MD, FAHA; Katherine J. Hoercher, RN;
Alec Vahanian, MD; Robert O. Bonow, MD, FAHA; William O'Neill, MD, FAHA

Abstract—The incidence of valvular heart disease is expected to increase over the next several decades as a large proportion of the US demographic advances into the later decades of life. At the same time, the next several years can be anticipated to bring a broad transition of surgical therapy to minimally invasive (minithoracotomy and small port) access and the more gradual introduction of percutaneous approaches for the correction of valvular heart disease. Broad acceptance of these technologies will require careful and sometimes perplexing comparisons of the outcomes of these new technologies with existing standards of care. The validation of percutaneous techniques, in particular, will require the collaboration of cardiologists and cardiac surgeons in centers with excellent surgical and catheter experience and a commitment to trial participation. For the near term, percutaneous techniques will likely remain investigational and will be limited in use to patients considered to be high risk or to inoperable surgical candidates. Although current-generation devices and techniques require significant modification before widespread clinical use can be adopted, it must be expected that less invasive and even percutaneous valve therapies will likely have a major impact on the management of patients with valvular heart disease over the next several years. (*Circulation*. 2008;117:1750-1767.)

Key Words: AHA Scientific Statements ■ cardiac surgery ■ catheters ■ interventional radiology ■ surgery
■ valves ■ valvuloplasty

The incidence of valvular heart disease is expected to increase over the next several decades as the “baby boomer” demographic passes into advanced decades of life. Treatments for heart disease and primarily valvular heart disease (as medical treatments for atherosclerosis improve) are expected to represent one of the main arenas for maintaining good health in this aging population.¹

In the face of this challenge, advances in technology and the scientific understanding of the anatomy and pathophysiology of valvular heart disease are offering an increasing array of minimally invasive open-chest (surgical) and percutaneous (interventional) treatments of valvular heart disease (Tables 1 and 2). New percutaneous valve interventions have

been directed toward the 2 most frequent forms of valvular heart disease in the industrialized West: aortic stenosis (AS) and mitral regurgitation (MR), which account for >70% of the cases of acquired valve disease in Europe.² At the same time, traditional cardiac surgical approaches via median sternotomy are being minimized by the application of smaller sternotomy and nonsternotomy strategies aided by robotic or video-assisted technologies.

The advance of percutaneous therapy for valve disease has not been unheralded; such clinical strategies were introduced as early as the 1950s with simple catheter devices to treat pulmonic stenosis. Treatment for stenotic lesions matured in the early 1980s with the advent of balloon valvuloplasty,

The American Heart Association makes every effort to avoid any actual or potential conflicts of interest that may arise as a result of an outside relationship or a personal, professional, or business interest of a member of the writing panel. Specifically, all members of the writing group are required to complete and submit a Disclosure Questionnaire showing all such relationships that might be perceived as real or potential conflicts of interest.

This statement was approved by the American Heart Association Science Advisory and Coordinating Committee on September 25, 2007. A single reprint is available by calling 800-242-8721 (US only) or by writing the American Heart Association, Public Information, 7272 Greenville Ave, Dallas, TX 75231-4596. Ask for reprint No. 71-0435. To purchase additional reprints, call 843-216-2533 or e-mail kelle.ramsay@wolterskluwer.com

Expert peer review of AHA Scientific Statements is conducted at the AHA National Center. For more on AHA statements and guidelines development, visit <http://www.americanheart.org/presenter.jhtml?identifier=3023366>.

Permissions: Multiple copies, modification, alteration, enhancement, and/or distribution of this document are not permitted without the express permission of the American Heart Association. Instructions for obtaining permission are located at <http://www.americanheart.org/presenter.jhtml?identifier=4431>. A link to the “Permission Request Form” appears on the right side of the page.

© 2008 American Heart Association, Inc.

Circulation is available at <http://circ.ahajournals.org>

DOI: 10.1161/CIRCULATIONAHA.107.188525

Table 1. Interventional Approaches to Valvular Heart Disease

Conventional Surgery	Minimally Invasive Surgery	Percutaneous
External access		
Median sternotomy (complete)	Partial sternotomy Minithoracotomy Thoracoscopy (PORT ACCESS or robotic)	Femoral vascular access
Cardiac access/protection		
Cardioplegic arrest	Cardioplegic arrest	Without cardioplegic arrest (rapid pacing)
Circulatory support		
Use of cardiopulmonary bypass	Use of cardiopulmonary bypass	Without cardiopulmonary bypass
Valve intervention		
Valve replacement	Valve replacement	Direct (edge-to-edge) repair†
Valve repair	Valve repair	Indirect (coronary sinus) repair†
	Sutureless valve replacement	Indirect (transventricular) repair†
		Sutureless valve replacement*

*Aortic and pulmonic valves.

†Mitral valve.

which has become the predominant therapy for primary pulmonic and mitral stenosis lesions.^{3,4} In contrast, outcomes after percutaneous aortic balloon valvuloplasty have been largely unfavorable, and this procedure is now seldom performed because of its risks and short-lived benefits.⁵ These contrasting results highlight the current perils of uniform and uncritical embracing of a new generation of technologies for the treatment of valvular heart disease, which have thus far been applied in only a few hundred cases in clinical trials.

Although innovations in the treatment of valvular heart disease create significant new treatment opportunities, they also will likely pose dramatic and potentially disruptive challenges to current practice patterns. Specifically, a predicted convergence of diagnostic, interventional, and surgical therapies is likely to largely rewrite the conventions for treating valvular disease while blurring the boundaries be-

tween the traditional domains of surgery, interventional cardiology, and noninterventional cardiology.

Realization of the potential benefits of these innovations may require a paradigm shift challenging long-standing principles in the evaluation and treatment of valvular heart disease. In this regard, tradeoffs between application of potentially less effective therapies may have to be weighed against potential benefits in terms of slowing or halting disease progression and improving symptoms and quality of life at a lower cost in terms of greater safety and less invasiveness. Compared with traditional surgical approaches, both short- and long-term evaluation of percutaneous devices for superiority in safety and noninferiority in efficacy will likely be needed.

Criteria for Success

The excellent results of contemporary surgery for valvular heart disease have set a high standard for new treatment

Table 2. Selected Percutaneous Approaches Specific to Valvular Pathology*

Valve Lesion	Approach	Device	Clinical Experience	Advantages/Disadvantages	
Aortic stenosis	Balloon valvuloplasty		Extensive	Poor durability	
	Valve replacement	Cribier-Edwards valve	Phase I	Antegrade approach: complex (simplified retrograde approach)	
		CoreValve	Phase I	Improved design features	
Mitral regurgitation	Edge-to-edge repair	E valve	Phase II	Primarily indicated for leaflet prolapse	
		Annuloplasty	Cardiac Dimensions Carillon	Phase I	Coronary sinus approach: redesigned
			Edwards Monarc	Phase I	Coronary sinus approach: redesigned
	Transventricular	Viacor	Phase I	Coronary sinus approach	
		Coapsys	Phase II	Indicated for annular dilatation/functional MR	
Mitral stenosis	Balloon valvuloplasty		Extensive	Effective	

*Approved for clinical use or in clinical trials.

strategies. Specifically, it will be important to consider that the operative mortality rate of aortic valve replacement (AVR) for AS and mitral valve repair for MR is low (<5%) and long-term results are excellent for up to 20 years (freedom from reoperation rates >70%), although these results vary widely, depending on patient comorbidities and the long-term complications associated with tissue valve durability and mechanical valve thromboembolic events.⁶⁻⁹

It also will be essential in these evaluations to consider that patients referred for valvular interventions today often are elderly and have increased surgical risk associated with congestive heart failure, emergency nature of the operation, left ventricular (LV) dysfunction, presence of coronary disease, previous surgery, and most important, presence of severe comorbidity.^{2,6} Candidates for less invasive procedures may present a different risk profile than currently referred patients (both at the high and low ends of the spectrum of risk); therefore, comparisons with current outcomes standards may not be appropriate.

If the rational application of new valve disease treatments is to be achieved, measures of invasiveness and effectiveness also will have to be weighed against the realities of patient expectations in potential patient candidate pools (those who currently may or may not be referred for surgery) and against the patients' perceptions of risks and benefits, ranging from issues of discomfort and incapacitation to the cosmetics of surgical scars. On the level of health economics, these outcomes will require analysis in rigorous cost-benefit models, weighing dollars spent against days of quality life gained and the long-term potential cost of temporizing more definitive corrections of valve pathology and of multiple possible follow-up interventions.

Finally, as clinical trials lead to regulatory approvals of new devices and techniques, it will be important to apply valid diagnostic testing, reasonable outcomes standards, and acceptable parameters of evidence and follow-up to ensure the appropriate adoption and dissemination of these innovations. These parameters will need to be accompanied by reasonable goals and safe methodologies for teaching these new strategies and techniques to appropriate cardiac practitioners and sites.

On the basis of these considerations, the present report describes and evaluates the status of new percutaneous and minimally invasive strategies for the treatment of valvular heart disease (Table 1). Minimally invasive valve surgery includes a group of operative approaches that use small chest wall incisions (eg, ministernotomy, minithoracotomy, and endoscopic and robotic procedures) to gain access to the mitral valve (Figure 1). All of these operations currently require cardiopulmonary bypass and an incision into the aorta or left atrium. Therefore, the term *minimally invasive* refers to a small chest wall incision that does not include a full sternotomy. Clinical data regarding the potential risks and benefits of percutaneous valve procedures and minimally invasive valvular heart surgery are compared with traditional open (median sternotomy) procedures.

The present analysis includes standard risk-benefit considerations (ie, morbidity and major adverse cardiac events—mortality, stroke, myocardial infarction, and rehospitalization—versus improvements in hemodynamics, survival, and

quality of life). In addition, this analysis includes consideration of risks and benefits uniquely relevant to these innovative methodologies, including issues of compromised surgical exposure, potential vascular dissection, and inadequate de-airing of the heart and embolization versus potentials for decreased bleeding and transfusion rates, less pain, and shorter length of hospital stay.

The indications for and risks and benefits of percutaneous procedures, including mitral leaflet repair, direct and indirect (coronary sinus, transventricular, and extramural) annuloplasty approaches, and percutaneous AVR are reviewed in Table 2. In these analyses, special consideration is given to the new therapeutic dilemma of balancing expectations for more durable therapy typically expected with surgical treatments with acceptable levels of temporizing pathophysiology and symptomatology with less invasive percutaneous approaches.

Current Substrate for Valvular Interventional Therapy

Insights into the current management of patients with valvular heart disease can be gained from the Euro Heart Survey, a study conducted over a 4-month period in 2001 in 92 centers from 25 European countries that prospectively included 5000 patients from surgical and medical cardiology departments and outpatient clinics.² Most significantly, this survey showed that as many as one third of elderly patients with severe symptomatic AS, and a similar number of patients with MR, were not referred for surgery by the attending practitioner.¹⁰ It is very likely that the extent of nonreferrals from the cardiologist's office or, even more so, the general practitioner's office is even higher. Whether this European experience is similar to practice in the United States is uncertain and is currently being evaluated by a number of investigators.¹¹ Application of a next generation of valve therapies, however, will need to be measured against the context of these current perceptions and practices.

The most striking characteristics of patients who are not referred for surgery are their older age, lower LV ejection fraction, and higher incidence of comorbidity. Given the increasing age and inherent growing degree of comorbidity in patients presenting with valve disease in industrialized countries, it is likely that patients at increased risk or with contraindications for surgery will remain a persistent challenge and will become potential candidates for interventions that are viewed as potentially safer (ie, associated with lower acute morbidity and mortality and event-free survival). It will therefore be important to use guidelines and objective outcomes evaluations incorporating risk stratification scores in assessing the results of new valve therapies in these patients.¹²

Important to this analysis of current practices is the further observation that although mitral valve repair is performed in 90% of the cases in experienced centers, only half of the patients undergoing surgery for severe MR receive valve repair, according to the Euro Heart Survey and the Society of Thoracic Surgeons Database¹³; the other patients undergo mitral valve replacement, which is associated with inherent increases in mortality and morbidity.^{2,6} The incidence of valve repair is even lower, the operative risk is higher, and

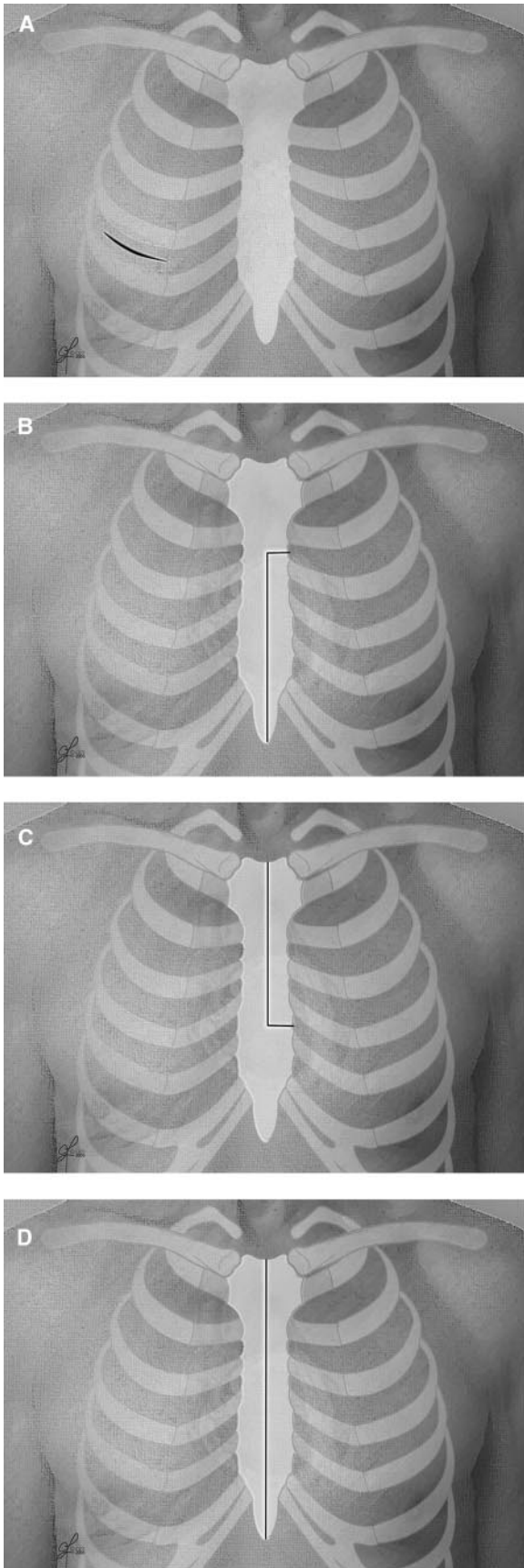


Figure 1. Minimally invasive incisions. A, right anterior minithoracotomy (mitral valve access); B, lower hemisternotomy; C, upper hemisternotomy; and D, full sternotomy.

long-term results are less satisfactory with a higher rate of recurrence of MR in the substantial subset of patients with MR secondary to rheumatic disease, endocarditis, or cardiomyopathy. Thus, it also will be important to these considerations to take into account real-life practices as opposed to those reported in the literature.

Minimally Invasive Surgical AVR

The surgical correction of aortic valve disease, predominantly via valve replacement, is typically a well-tolerated and durable intervention. Clinical outcomes after AVR have been quite good, with an overall operative mortality rate for isolated AVR of 4%.⁶ Despite favorable AVR results as a whole, data in cardiac surgery databases may be misleading and poorly predictive of opportunities for less invasive remedies. For example, the operative mortality rate for AVR in patients ≥ 80 years of age is as great as 8% to 15%.^{14–20} Furthermore, in the rapidly aging US population, the number of elderly patients with significant comorbidities is steadily increasing, and for many patients, both the natural history of untreated AS and results after the traditional on-pump AVR through a median sternotomy may be worse than conveyed by overall outcomes data.^{11,20}

Surgical replacement of the aortic valve traditionally has required conventional open-chest surgical techniques performed under general anesthesia. The heart is exposed through an incision the length of the sternum (median sternotomy) and connected to a heart-lung machine that assumes cardiopulmonary functions during the procedure (cardiopulmonary bypass). The advantage of the median sternotomy compared with less invasive techniques is that it affords the most options for pump cannulation and myocardial preservation, providing unsurpassed access to the heart and great vessels, especially when dealing with potential intraoperative technical difficulties or other complications such as a fragile, torn, or dissected ascending aorta. Not uncommonly, the cardiac surgeon also may be faced with situations that require more than simple AVR such as a small aortic root, annuloaortic ectasia, an ascending aortic aneurysm, or extensive aortic calcification, the extent of which may not always be accurately identified preoperatively.²²

In general, the median sternotomy also is well tolerated, with minimal postoperative discomfort and a healing/infectious complication rate on the order of 1% to 2%. On the other hand, the median sternotomy and use of cardiopulmonary bypass are potential contributors to complications in high-risk individuals and are commonly perceived with great apprehension by patients and referring physicians alike. Aside from the physiological risk factors concomitant to open heart surgery, these concerns represent significant (psychological) barriers to the application of open heart surgery.

Minimally Invasive Surgical Techniques for Aortic Valve Disease

Given both the obstacles toward traditional surgical intervention and an apparently large population of higher-risk patients, a number of different techniques and approaches other than median sternotomy have been proposed to create safer and less invasive AVR procedures. These alternatives have

included primarily a mini right anterior thoracotomy through the second or third intercostal space and alterations of the median sternotomy approach (T, J, L, reversed C, S, and an inverted V hemisternotomy; Figure 1) while retaining standard cardiac surgical techniques for valve replacement.^{22–29} Performance of these procedures through small (≤ 2 in) incisions while avoiding median sternotomy provides considerable psychological comfort to patients undergoing these procedures and may confer additional benefits in terms of improved recovery and reduced activation of inflammatory cascades as compared with standard open procedures.

Although actual results vary considerably among centers, the other overall advantages of such approaches have been reported to include less postoperative pain, improved cosmetics, less blood loss, fewer pulmonary and wound complications, and shorter length of stay.^{30–35} In this context, a multitude of preoperative variables may influence a surgeon's decision to modify the standard surgical approach toward less invasive strategies, but the primary determinant is likely to be the surgeon's level of experience with such procedures, and consistent with the above-noted risk considerations, the great majority of AVR procedures are thus far still performed through a full median sternotomy.

Despite the potential advantages of nonsternotomy approaches to the aortic valve, one may argue that significant gains in reducing major perioperative complications such as death (early and late), myocardial infarction, and stroke may be unobtainable as long as the cardiopulmonary bypass circuit and cardioplegic arrest continue to be part of these minimally invasive aortic valve operations; that is, changing only the incision results in only a small incremental benefit for the patient. In fact, in the hands of cardiac surgeons with lower volumes of valve cases, complication rates with a nonsternotomy approach may actually be higher because cardiopulmonary bypass and cardiac arrest times run longer as a result of performing the operation through limited access.^{35–37}

Consequently, although the initial invention and subsequent refinement of the cardiopulmonary bypass circuit are substantially responsible for making valve replacement surgery technically possible and progressively safer in most patients, it is generally accepted that the greatest promise may be offered by new aortic valve technology that can partially or completely eliminate the use of any assisted circulation. Two specific surgical approaches have been offered for such off-pump treatment of aortic valvular disease: transapical AVR (also referred to as direct-access AVR) and an off-pump apicoaortic conduit insertion (also referred to as aortic valve bypass). Although both methods currently propose an open thoracotomy, the potential exists for less invasive methods using either small, less traumatic incisions or a ports-only (thoracoscopy) approach.

Transapical AVR

Transapical AVR using a thoracotomy has been described in animal studies and recent clinical reports.^{38–43} The Ascendra valve (Edwards Lifesciences, Irvine, Calif) was implanted transapically in 30 consecutive high-risk patients with a predicted operative mortality rate (as determined by the Euroscore predictive model of preoperative risk factors) of

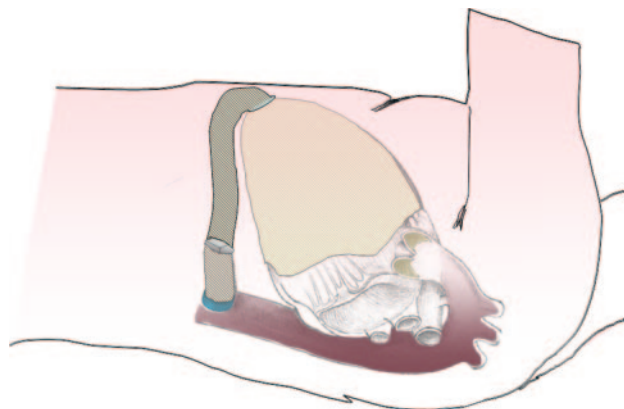


Figure 2. Schematic depicting position of left ventricular apicoaortic valved conduit for aortic valve bypass.

27%, with a resultant 30-day mortality rate of 7%.⁴¹ Access to the cardiac apex during such procedures is achieved through a left anterolateral thoracotomy along the sixth interspace. The transapical access site is gradually dilated, and the crimped valve is introduced inside the diseased native aortic valve. Techniques important in the percutaneous procedure have proved helpful with the initial transapical experience, including predeployment balloon aortic valvuloplasty and the use of rapid pacing to temporarily halt forward flow.

Investigators of the transapical approach point out that many of the disadvantages of the first-generation percutaneous approaches discussed below may be eliminated by virtue of straight-line access to the aortic valve afforded by use of the LV apex as the entrance site. Shortening and straightening the path to the aortic valve decreases the potential for endovascular trauma, embolization of atheroma from the aorta associated with retrograde approaches, and mitral leaflet injury from antegrade approaches. In addition, the transapical approach provides the ability to use other technology, such as embolic protection devices and temporary ventricular support, or the potential for the addition of mitral valve repair and/or ventricular remodeling technology.

Ventriculoaortic Valved Conduit

Another less invasive, potentially safer alternative to traditional AVR for treating high-risk patients with aortic valvular disease (primarily AS) is the use of ventriculoaortic valved conduit, which essentially bypasses the native aortic valve.^{44–48} The insertion of an apicoaortic conduit, first used clinically in 1955 and previously used for pediatric patients with complicated LV outflow tract obstruction, creates a second outflow tract from the left ventricle to the descending aorta, and the diseased, native aortic valve left in situ (Figure 2).

Aortic valve bypass has the advantage of completely avoiding the diseased root and solving several potential problems of percutaneous and transapical AVR such as coronary artery encroachment, valve prosthesis migration, paravalvular leak, and plaque embolization. Patient-prosthesis mismatch also is less concerning because the new aortic valve orifice will be additive to the native valve. Additionally, there already are long-term hemodynamic data supporting the beneficial effects of the apicoaortic conduit.⁴⁸

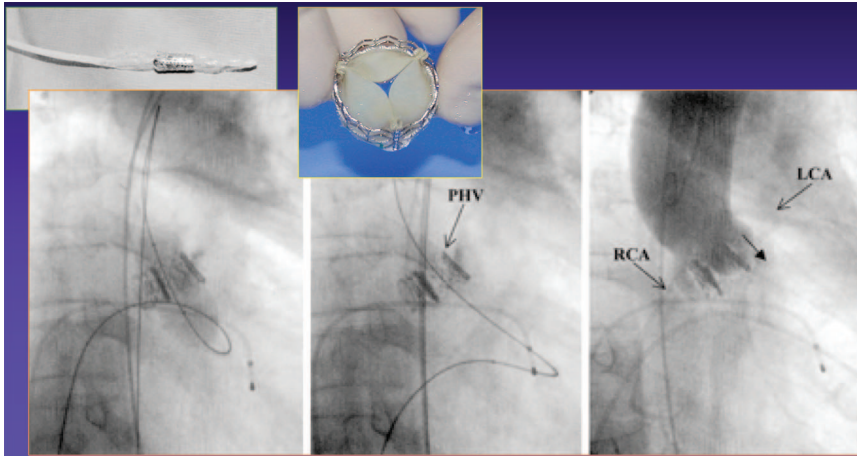


Figure 3. Percutaneous aortic valve placement. Fluoroscopic imaging of procedure. Insets depict valve delivery catheter and stented valve. PHV indicates percutaneous heart valve; RCA, right coronary artery; and LCA, left coronary artery. Courtesy of Alain Cribier.

A limitation of the apicoaortic conduit approach is that it is a treatment for pure AS; any significant aortic insufficiency is an absolute contraindication. The ability to create a second LV outflow tract also is determined to some extent by the quality of the descending aorta, which is sometimes diseased in this patient population. Furthermore, in its current design and clinical implementation, apicoaortic conduit devices and methods are not suitable for an off-pump or endoscopic approach. Novel devices designed to perform this procedure off pump with technical ease are under development and currently in the long-term animal study phase.

Additional Surgical Alternatives

Another less invasive option for patients with aortic valve disease is a “sutureless” device deployed through a (mini) thoracotomy or a traditional surgical approach. Patients are placed on cardiopulmonary bypass through a median sternotomy or minimally invasive approach, and the native valve is resected via traditional means. A modified biological valve is then secured to the aortic root with a stent or alternative sutureless method. Such devices are currently under preclinical and clinical investigation. Although this strategy requires an operative approach, the ischemic and cardiopulmonary bypass times would be expected to be shorter than for traditional AVR surgery, assuming appropriate valve deployment.

Percutaneous AVR

Open, on-pump surgical AVR with mechanical or bioprosthetic valves, as described above, is a time-tested, reliable, reproducible, and life-saving treatment for aortic valve disease. If 5-year follow-up were taken as a minimal basis for comparison, this benchmark would include overall survival rates of 85% and event-free survival rates of 71%, with 70% (actuarial) survival rates even in octogenarians.^{6,14,15} Five-year survival after AVR has been reported to be 95% of that of age- and gender-matched individuals in the (Swedish) general population.¹⁶

Current iterations in standard tissue valve design deliverable via a surgical approach also have achieved remarkable outcomes in terms of valve durability. A meta-analysis of 8 studies encompassing >2500 implants demonstrated a median interval to structural valve deterioration (in a typical 65-year-old male) of >20 years.⁴⁹

In the context of these outcomes, it must be considered that the introduction of general anesthesia, sternotomy or thoracotomy, and cardiopulmonary bypass engenders incremental risk, especially in the (growing) extremely aged population and those with medical comorbidities. In addition, certain technical factors such as heavily calcified aortas, previous mediastinal radiation, multiple prior sternotomy procedures, severe lung disease, or coagulopathies further mitigate the benefits versus risks of a surgical approach. Given these considerations, percutaneous approaches to the aortic valve are currently being focused toward high-risk populations.

Percutaneous attempts at relief of AS initially involved balloon aortic valvuloplasty. This approach, however, resulted in only modest hemodynamic improvement, with a high incidence of restenosis and a long-term survival not different from the natural history of AS.⁵⁰ Although recent modifications of the balloon aortic valvuloplasty technique, including the use of rapid ventricular pacing to arrest cardiac output and external beam irradiation to prolong the durability of balloon aortic valvuloplasty, have rekindled some interest in this technique for inoperable patients, current scientific interest has shifted from balloon aortic valvuloplasty to percutaneous AVR for the treatment of AS.^{51,52}

Clinical Trials of Percutaneous Aortic Valves

A review of the clinical data available for 2 types of percutaneous aortic valves illustrates the state of development of these devices, which are balloon deployable or self expanding. The Cribier-Edwards valve (Edwards Lifesciences), currently available in 23- and 26-mm-diameter sizes, is constructed of a stainless steel stent to which equine pericardium is sewn in a trileaflet fashion (Figure 3). With this device, valve area after percutaneous valve deployment increased from 0.5 to 1.7 cm² for up to 9 months in a series reported by Cribier, who pioneered the technique, and coworkers.⁵²

The antegrade implantation technique originally described by Cribier et al is extremely complex. It involved transseptal puncture; flotation of a balloon-tipped catheter through the left atrium, left ventricle, and aortic valve to the descending aorta; and arterial exteriorization of the intravascular guide-wire (Figure 3). The technique has proved too complex for widespread dissemination, particularly with the first-generation device.

Cribier also treated some patients with a retrograde transarterial approach, and Hanzel et al⁵³ reported the successful deployment of a percutaneous aortic valve through a retrograde approach. Conceptually simpler and more reproducible, reliable retrograde passage of the stent valve is facilitated by the introduction of a flexible, steerable delivery catheter. The rapid enrollment of patients by Webb et al⁵⁴ using this approach reflects its greater ease of use compared with the antegrade approach. At the time of the writing of this article, a phase I US trial has completed enrollment of a first cohort at 3 sites, and a pivotal US trial of this technology is being formulated.

Clinical data also are available for a porcine pericardial tissue valve pioneered by Grube et al⁵⁵ that is sewn inside a self-expanding nitinol stent (CoreValve, Irvine, Calif). The first generation of this system required retrograde passage and placement with femorofemoral bypass or with percutaneous left atriofemoral LV assist. The profile has been reduced from 24F to 18F and no longer requires cardiopulmonary support in all cases. Both the Cribier-Edwards and CoreValve devices have been used in high-risk patients with predicted Euroscores >30%, with actual 30-day mortality rates <10%.^{52–56}

Limitations and Potential of Percutaneous AVR

Although there is enormous enthusiasm for percutaneous AVR, it must be emphasized that this technology is in its infancy. Novel complications such as device migration or embolization, mitral valve laceration, and paravalvular aortic insufficiency have already been reported.^{52–56} Other developmental issues that still need to be addressed and that are discussed in the “Final Considerations” section include optimization of access routes, further reduction in delivery system and prosthesis profile, and development of balloon-expandable versus self-expanding stent platforms and repositionable and retrievable devices. The extent and nature of the valve and valve annulus pathology are important elements in these considerations.

Severe calcification of the native aortic valve, particularly asymmetric calcification, can make it difficult to cross the aortic valve with a large-caliber prosthesis. At least 1 case of obstruction of the left main coronary ostium by a calcific nodule during a percutaneous AVR has been reported. This complication may be resolvable by echocardiographic observation of leaflet nodules and the motion of leaflet calcification during balloon predilatation of the valve.

Even though prosthesis size is determined on the basis of accurate pre-measurements of the aortic annulus by transesophageal echocardiography (TEE) or computed tomography (CT) in current trials, and patients with annulus diameters that are too large for the available devices are excluded, paravalvular leaks have been a significant concern for the percutaneous aortic valve devices developed thus far. The frequency of leaks, however, has already been diminished by the use of larger-diameter balloon-expandable valves (26-versus 23-mm nominal stent diameter). Future devices will need to have larger diameters or cuffs to prevent such leaks, especially in patients with a dilated aortic root.

As these challenges are met, additional opportunities may present themselves. For example, patients who have under-

gone previous AVR with a bioprosthesis may be good candidates for percutaneous valve-in-valve procedures that have already been performed successfully in clinical studies of percutaneous pulmonic valve replacement. Patients with aortic insufficiency, in particular, those with bicuspid aortic insufficiency and no or minimal aortic root dilation, may also be candidates for percutaneous therapy. Larger devices and fixation systems that will anchor in less deformed valves, however, will likely be necessary for these applications.

Minimally Invasive Mitral Valve Surgery

As with aortic valve surgery, multiple alternatives to sternotomy for mitral valve surgery have been described in the literature in the past decade. Early studies, however, have included only small numbers of patients and a paucity of data, and claims of reductions in postoperative discomfort and shorter recovery times have until recently been unsubstantiated by randomized trials. Now, longer-term data suggest that minimally invasive mitral valve surgery not only improves cosmetics but also reduces blood loss and shortens hospital length of stay.^{57–60}

Minimally Invasive Surgical Techniques for Mitral Valve Disease

The most important of the minimally invasive mitral valve techniques are parasternal access, partial sternotomy, PORT ACCESS systems (Edwards Lifesciences), robotically assisted mitral valve surgery, and a simplified minithoracotomy approach. Unfortunately, there are few direct comparative data among these different approaches.

Parasternal Approach

Cosgrove et al⁶⁰ first described a less invasive technique for valvular heart surgery in 1998. Their right parasternal approach includes a 6- to 8-cm incision to the right of the sternum with resection of the third and fourth costal cartilages. A 5-cm groin incision is used to cannulate the femoral vein and artery to establish cardiopulmonary bypass. This technique provides excellent exposure of the mitral valve via a transeptal approach, which facilitates complex mitral valve repairs.

Initial experience with this approach was favorable, with excellent cosmetics, reduced pain, and less blood loss than with standard sternotomy.⁶⁰ However, (generally transient) instability of the chest wall was noted with this technique, resulting in a slight bulging of the chest wall during coughing. Sacrifice of the right internal thoracic artery also is a potential concern should the patient ever require coronary artery bypass grafting. Finally, the transeptal approach to the mitral valve utilized with this technique transects the artery to the sinoatrial node, which causes temporary bradycardia in many patients.

Excellent results have been reported recently with a modified parasternal approach that eliminates open femoral cannulation in most patients and changes the incision slightly to reduce the risk of chest wall herniation.⁵⁸ Comparing the parasternal approach with conventional sternotomy, Aklog and colleagues⁶¹ reported reduced recuperation time with an accelerated return to normal activity level.

Partial Sternotomy

The mitral valve also can be accessed via partial upper or lower sternotomy, which leaves the manubrium intact (Figure

1). The rationale for this approach is that median sternotomy is the incision with which cardiac surgeons are most familiar, and with a modified partial sternotomy for minimally invasive mitral valve surgery, the surgeon's learning curve is shortened. Partial sternotomy provides a familiar operative field, standard approaches to the left atrium (extended trans-septal for upper sternotomy and lateral left atriotomy for lower sternotomy), and central cannulation for cardiopulmonary bypass in most cases. The addition of vacuum-assisted venous drainage to these techniques allows the use of smaller, less obstructive cannulas in the surgical field. Vacuum-assist also reduces the priming volume of the cardiopulmonary bypass circuit, prevents air locks, and keeps the field dry. Compared with full median sternotomy, partial sternotomy has been associated with similar rates of mitral valve repair (96% in degenerative mitral valve disease), increased patient satisfaction, reduced surgical trauma and blood loss, shorter intensive care unit and hospital lengths of stay, and decreased healthcare costs.^{29,62}

Minithoracotomy

A partial or total sternotomy can be avoided altogether by the right thoracotomy approach. In most instances, minimally invasive mitral valve surgery via a small anterolateral right thoracotomy entails peripheral (femoral) cannulation for cardiopulmonary bypass. With this technique, a 4- to 8-cm incision in the fourth intercostal space provides access to the left atrium. Since the first report of mitral repair through minithoracotomy by Carpentier et al,⁶⁴ a variety of adjunctive techniques, including PORT ACCESS technology and robotics, have been developed to facilitate mitral valve surgery via a small thoracotomy and have been responsible for the markedly increased application of this technique in recent years.

PORT ACCESS

PORT ACCESS technology first entered clinical practice in 1997. This technique includes the use of a variety of catheters designed specifically for institution of peripheral bypass and administration of cardioplegia. The cornerstone of this system was an endoluminal aortic balloon used to facilitate cardiac arrest without the need for standard aortic cross-clamping. There were, however, 2 major concerns at the time PORT ACCESS techniques were introduced: the risk of aortic dissection and the need for special techniques to remove intracardiac air after valve surgery.

Technical modifications, including more flexible guidewires and strict adherence to the Seldinger technique for catheter placement, have significantly reduced the risk of aortic dissection. Several strategies, including the insufflation of (relatively soluble) CO₂ gas into the surgical field, have been developed for air removal; these have resulted in a risk of stroke similar to that associated with standard open-chest mitral valve procedures.

One of the largest series of PORT ACCESS valvular surgery was published by Grossi and colleagues.^{59,65} They reported decreased length of hospital stay, decreased blood usage, and a decreased infection rate with comparable 1-year echocardiographic results compared with patients undergoing the standard

sternotomy approach. PORT ACCESS techniques did not increase operative morbidity or mortality rates in their experience.

The Port Access International Registry, initiated in 1997 and terminated in 1999, analyzed outcomes of 491 isolated mitral valve repairs and 568 isolated mitral valve replacements.^{67,68} In this series, the operative mortality rate was 1.6% for mitral repair and 5.5% for mitral replacement; multivariable analysis demonstrated that predictors of death were reoperation, older age, and mitral valve replacement. Overall, the results from this registry were comparable to those of conventional sternotomy and demonstrated that PORT ACCESS was a viable option for isolated mitral valve surgery.

On the other hand, other reports of PORT ACCESS technology were disappointing, with a reported mortality rate of nearly 10%, a high rate of morbidity, and no decrease in postoperative pain. Mohr and colleagues⁶⁹ described severe complications associated with the peripheral vascular access and the use of retrograde systemic perfusion. PORT ACCESS surgery has therefore come to be viewed primarily as an important evolutionary step in the development of less invasive cardiac surgery.

Robotics

The lesson of PORT ACCESS surgery was primarily that the mitral valve could be approached through a small anterior thoracotomy. Although appropriate surgical instrumentation could provide the surgeon an excellent view of the mitral valve, in some cases, working in a tunnel-like geometry could also be technically challenging. This limitation has been overcome by the development of small-caliber robotic instruments that incorporate articulating instrument motion and nondirect (ie, camera) visualization of the surgical field.

In robotic mitral valve surgery, the surgeon sits at a console and directs robotic instruments, which are inserted through small chest wall incisions. In most instances, a very small thoracotomy is created to introduce the valvular prosthesis or annuloplasty ring. The first robotically assisted mitral valve surgery was reported in 1998; in this experience, a voice-controlled device was used to facilitate mitral valve repair in 8 consecutive patients.⁷⁰

The da Vinci system (Intuitive Surgical, Inc, Sunnyvale, Calif) includes a combination of 3-dimensional visualization and microinstrumentation, providing a full range of motion in tiny spaces, with motion scaling and tremor elimination. Results from a 10-center trial of robotic mitral valve repair in 112 patients with the da Vinci surgical system were published in 2005.⁷¹ In this series, operative times were longer compared with conventional sternotomy. However, as experience and familiarity increased, there were progressive declines in cross-clamp, bypass, and overall operative times.

Individual experiences with robotically assisted mitral valve repair parallel those of the randomized trials.⁷² In 1 single-center experience with 25 patients, 80% of patients were extubated in the operating room, and the average length of hospital stay was <48 hours.⁷³ However, among those patients discharged in <24 hours, 37% required hospital readmission, suggesting the need for further study to identify those patients who can safely go home within 1 day.

Although experience with robotic surgery is growing and even early experience indicates that this approach may

provide clinical benefits (reduced surgical trauma, decreased pain, excellent cosmetics, and a very short hospital stay), longer follow-up is needed to determine, for example, the durability of valve repair with this technique, a key measure of the success of mitral valve surgery. Furthermore, the populations included in published series of robotically assisted surgery have generally been young and healthy and without important LV dysfunction. The use of this technology in an older, sicker patient requires further investigation. Finally, although robotic mitral valve surgery has resulted in a decrease in length of stay and reduced hospital per-case costs, the absolute cost savings associated with this technology remain unresolved because of the large capital expenditure for the robot and all its components.

Simplified Minithoracotomy

Some groups familiar with both PORT ACCESS and robotic techniques have recently popularized a simplified minithoracotomy approach to mitral valve surgery, relying on more conventional instrumentation but still working through a small right thoracotomy. Peripheral cannulation with low-profile, high-flow cannulas and direct transthoracic aortic occlusion with a flexible clamp facilitate this procedure.⁷⁴ In most instances, direct visualization of the valve is sufficient, and surgical cameras are not necessary.

In a recent study of 241 patients having a small anterolateral thoracotomy in the fourth intercostal space, transthoracic aortic clamping, and direct vision of the mitral valve, mid-term results were comparable to those achieved with full sternotomy.⁷⁵ Other investigators have also recommended the transthoracic clamp technique over the PORT ACCESS endovascular cardiopulmonary bypass system, demonstrating shorter surgical and cross-clamp times and lower instrumentation costs. For example, although the PORT ACCESS technique adds \$3000 in cost to each case, approaches that use the transthoracic clamp technique add only \$200.⁷⁶

The goals of minimally invasive mitral valve surgery thus center on application of techniques that appeared to enable achievement of technical results identical to those reported with sternotomy and include decreased patient apprehension preoperatively, better cosmetics, less surgical trauma, reduced blood loss, and faster recovery. With a decade's worth of clinical data, it is clear that these milestones have been achieved by the small but growing number of surgeons who use these approaches. The demonstration that complex mitral operations can be performed minimally invasively with excellent clinical results represents a triumph of surgical expertise and technology.

The next steps in the development of minimally invasive mitral valve surgery include further refinements in technology to make the incisions even smaller, more widespread adoption of these practices in a great number of surgical centers, and overall evolution of these techniques to achieve a closer approximation of percutaneous techniques in terms of surgical trauma. Although reduced surgical trauma may yield faster recovery times, the physiological perturbations associated with requisite cardiopulmonary bypass nevertheless remain a fundamental obstacle to reduced invasiveness of such strategies.

Percutaneous Mitral Valve Approaches

Percutaneous approaches for correcting mitral valve disease have developed along the lines of surgical approaches. The percutaneous correction of MR, however, has posed significant technical challenges that have only recently been addressed with advances in device engineering and novel concepts for catheter approaches to valve repair.

Percutaneous Techniques for Mitral Valve Repair

Leaflet repair and direct versus indirect (coronary sinus) annuloplasty represent the predominant percutaneous approaches to local repair of the mitral valve apparatus currently in device and procedure development. Other approaches attempt to realign the mitral valve coaptation by addressing ventricular mechanics.

Leaflet Repair

Alfieri et al⁷⁷ first described a surgical approach to leaflet repair approximately 10 years ago that uses a suture to plicate the free edges of the mitral leaflets and to create a double-orifice mitral valve. Alfieri et al⁷⁸ reported a 5-year freedom from reoperation with his procedure of 90%, and Maisano et al^{79,80} recently published a 12-year follow-up of patients treated with isolated edge-to-edge repair. These studies suggested the feasibility of an endovascular application of this technique in carefully selected patients. Of the various approaches to percutaneous mitral valve repair, one of the most advanced in terms of clinical investigation involves percutaneous modification of this edge-to-edge technique. In this technique, transeptal access to the mitral valve allows placement of a metal clip on the mitral leaflets, allowing creation of a double orifice valve (Figure 4).⁸¹ The clip used in this procedure is made of cobalt-chromium alloy and is covered with Dacron fabric to facilitate tissue ingrowth.

Early animal work demonstrated that a tissue bridge forms over the clip within 6 months, creating a double orifice morphology virtually identical to that seen late after a surgical repair.⁸² The edge-to-edge repair approach also has been accomplished with percutaneous suture-based technology, but this technique has been applied to only a small number of patients in phase I trials.

Despite encouraging initial clinical experience without major problems of mitral stenosis or recurrent MR reported by the Alfieri group and in the Endovascular Valve Edge-to-edge REpair Study (EVEREST) that is detailed below, it must be considered that the scarring associated with mitral clips might result in a natural history different from that with the Alfieri stitch. It must further be cautioned that the results of Alfieri et al were less favorable in cases when annuloplasty was not performed, and other investigators have reported less favorable (intermediate-term) outcomes than Alfieri et al, with 24% of patients developing recurrence of 3+ MR within 2 years of their procedure.^{79,83} Leaflet-based devices also do not address dilation of the mitral annulus, a common component of mitral insufficiency, and are therefore useful only in selected patients.

Annuloplasty Approaches

Recognition that the coronary sinus parallels the mitral annulus also has led to the development of a number of devices to create an annuloplasty via a coronary sinus approach. Most of these devices involve introduction of a

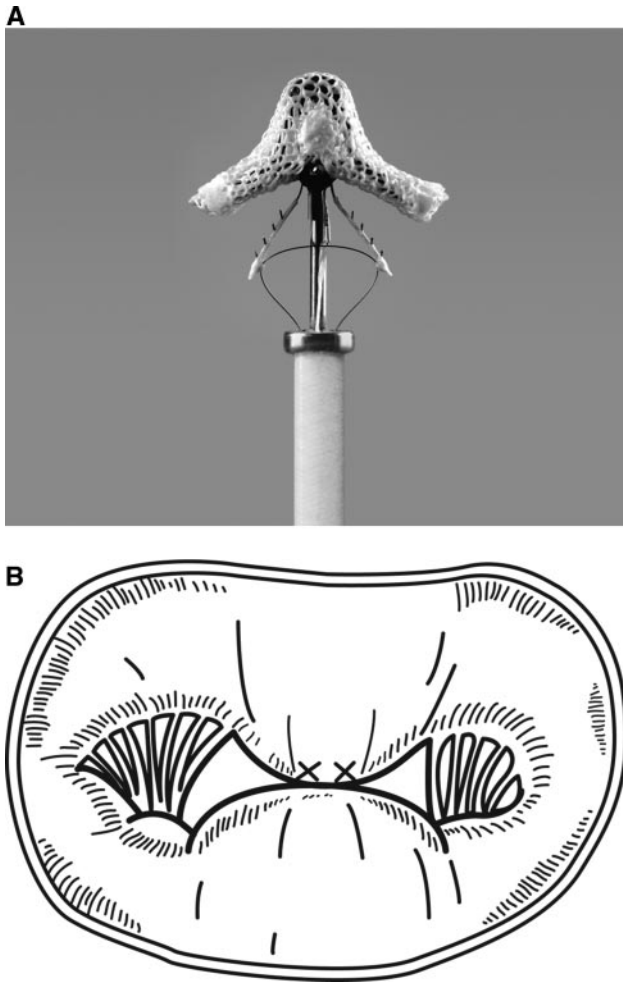


Figure 4. Percutaneous mitral valve repair. A, Cobalt-chromium clip. B, Double orifice configuration of repaired valve. Courtesy of Evalve Inc (Menlo Park, Calif).

transjugular guiding catheter into the coronary sinus and placement of an anchoring device in the distal coronary sinus, a tensioning element, and a proximal coronary sinus anchor.

Among these devices, the Cardiac Dimensions Carillon device (Kirkland, Wash) uses a nitinol wire element with proximal and distal anchors.^{84,85} In comparison, the Edwards Monarc (Irvine, Calif) device uses self-expanding stents connected by a spring-like bridge element that is held open by absorbable material in its interstices.⁸⁶ As the material dissolves over a 3- to 6-week time period, the bridge contracts and diminishes the mitral annular circumference. Human implantation of the first 2 of these devices was marked by early design-related failures. In the early phases of the phase I United States Clinical Trial of the Cardiac Dimensions Carillon device, the distal anchor failed to hold adequately. This resulted in removal of the devices before they were released or permanently deployed. Likewise, the Edwards device developed bridge fractures in 3 patients in a Canadian phase I experience. Both devices have been redesigned and are once again undergoing clinical investigation. A third device, the PTMA (percutaneous transvenous mitral annuloplasty) system (Viacor; Wilmington, Mass), places rigid elements into a plastic sleeve in the coronary sinus, placing pressure on the P2

segment of the posterior mitral leaflet with resultant diminution of the septal-lateral dimension.^{87,88} The Viacor device has been used in temporary intraoperative human experience, and permanent implantation trials are being initiated.

Despite these theoretical opportunities, early clinical experience has made it clear that the simple concept of coronary sinus mitral annuloplasty faces many challenges in execution. These limitations include the reality that the coronary sinus approach may be limited by the distance of the coronary sinus from the mitral annulus, and thus the annuloplasty is not direct. A second potential limitation of this approach is that the crossover of the coronary sinus on top of a left circumflex artery branch in many cases could lead to inadvertent, potentially deleterious compression of the coronary arterial vasculature. This limits the distance around the coronary sinus that an annuloplasty device may be delivered and thus may limit the efficacy of this approach. Finally, coronary sinus-based devices also do not address the anterior (intertrigonal) mitral annulus, which many consider to also be subject to dilation over time. Although these devices have not yet resulted in coronary sinus perforation or thrombosis or in distortion of the nearby circumflex artery in patients, perforations related to coronary sinus access have been reported. To address some of these issues, detailed imaging of the coronary sinus with CT has been used to assess the relationship of the coronary sinus to the circumflex coronary and to facilitate device length and anchor diameter selection.

As a consequence of the above considerations, a more direct approach to mitral annuloplasty that more closely approximates surgical suture plication has been developed in animal models. In animal testing of a suture plication technique, 20% reductions in annular circumference or absolute reductions in circumference of ≈ 1 cm with suture plication have induced a dramatic improvement in MR.⁸⁹ In a percutaneous approach to suture plication, a catheter is placed retrograde into the left ventricle and positioned behind the posterior mitral leaflet, directly abutting the mitral annulus. Anchors are placed in the annulus and connected with a drawstring that plicates the annulus when tension is applied. Clinically, open surgical suture plication has been associated with freedom from reoperation of $>90\%$, with $>80\%$ freedom from death, reoperation, and recurrent MR.⁹⁰ Percutaneous suture plication data are pending.

Combined Mitral and LV Remodeling

Finally, a novel off-pump surgical transventricular repair that involves placement of a tensioning cable directly through the LV chamber (Coapsys; Mycor, Maple Grove, Minn) has been developed to address mitral annular and ventricular dimensional corrections associated with mitral repair strategies.⁹¹ In this technique, anchoring pads on either side of the ventricle are used to allow the cable to apply tension across the LV chamber (Figure 5). This shortens the septal lateral dimension and remodels the LV chamber.

This approach is unique in that it is the only mitral repair to directly remodel the LV chamber, which has potential advantages in cases of functional MR. Significantly, aspects of the ventricular compression inherent in this approach also may address derangements of ventricular mechanics associated with

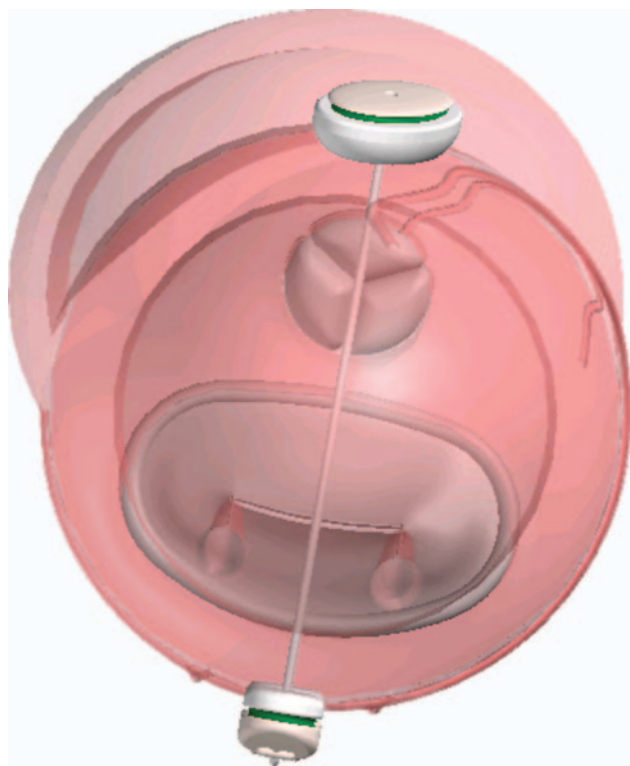


Figure 5. Transventricular mitral valve repair. Depiction of device consisting of 2 pads deployed on anterior and posterior ventricular surfaces with intervening chord.

dilated cardiomyopathies. It has been used in a number of patients in a phase I clinical trial, with durable results up to 1 year,⁹² and is undergoing phase II testing in the Randomized Evaluation of a Surgical Treatment for Off-Pump Repair of the Mitral Valve (RESTOR-MV) trial. A transpericardial percutaneous method that can reproduce the effects of the surgical approach is in development in early clinical trials.

An alternative approach to functional MR uses anchors placed in the coronary sinus and atrial septum to allow a tensioning cable to be placed across the left atrial chamber, which applies septal to lateral tension to reduce the septal-lateral dimension and the degree of MR.⁹³

Percutaneous Mitral Valve Replacement

Percutaneous mitral valve replacement has not yet been attempted in humans and is limited by several important issues. The asymmetric shape of the mitral annulus makes creating a replacement prosthesis challenging. Delivery of the device may require novel methods, and cardiopulmonary support may be needed. Anchoring of a device is likely to have different requirements in different types of MR. Other speculative considerations include retention of native valve tissue, an issue that is not critically important in aortic valve disease but which may result in obstruction of the LV outflow tract after mitral valve deployment. Higher closing forces on the valve may confer an increased risk of paravalvular leak compared with aortic valves; therefore, cuff design or anchoring and accurate device sizing are critically important.

Other challenges to percutaneous MVR also exist. Mitral annular dilation frequently is observed in patients with MR, and

this process may not be prevented by percutaneous valve replacement. Patients with rheumatic mitral stenosis have a foreshortened and restrictive subvalvular apparatus, which may interfere with valve function. Patients with severe mitral annular calcification also will pose a significant technical challenge.

Despite all of these considerations, less invasive mitral valve replacement may be a future possibility. Possible deployment routes include antegrade via a percutaneous transeptal approach, antegrade through the left atrium via a minithoracotomy, or retrograde through the LV apex via a minithoracotomy. In addition, sutureless devices could be deployed via traditional surgical methods with decreased ischemic and cardiopulmonary bypass times.

EVEREST: A Window Into Percutaneous Valve Trials

A potential blueprint for clinical study and development of percutaneous devices may be discernible in the experience gathered from the EVEREST II multicenter trials. As of October 2006, a total of >160 symptomatic patients (or asymptomatic patients with evidence of LV dysfunction) have been treated with this device. A phase I trial with 55 patients has been concluded, and >60 patients have been randomized to percutaneous treatment versus surgical mitral valve repair or replacement in the EVEREST II randomized trial.^{94–96}

Importantly, EVEREST I and II have adopted the 1998 American Heart Association/American College of Cardiology guideline criteria for defining the patient population for mitral valve repair requiring moderate to severe or severe regurgitation (3+ or 4+).⁹⁷ In addition, the severity of MR both before and after repair is assessed in this trial by a core echocardiography laboratory using the American Society of Echocardiography criteria for MR severity.⁹⁸ In comparison, prior experience with both diagnosis and therapy for MR has used purely subjective methods for assessing MR severity.

Among patients intended for clip placement in the EVEREST trial, degenerative MR was present in 83%, and functional MR was seen in 17%. Ninety percent have had a clip implanted at the time of the index procedure (38% have been treated with 2 clips). In the most recent cohort, clips have been successfully placed with resultant MR $\leq 2+$ in 90% of patients. About 70% have had $\leq 1+$ MR by core laboratory evaluation. The Kaplan–Meier freedom from death, mitral valve surgery, and MR $>2+$ has been almost 80% at 36 months (freedom from death, 99%; freedom from surgery, 87%).

Delivery of the clip device, however, has been associated with a steep learning curve. Navigation within the left atrium to place the clip coaxially in the mitral orifice requires nonstandard echocardiographic views and a remarkable degree of coordination and communication between the echocardiographer and interventional cardiologist. In addition, the technical skills necessary to maneuver the clip are novel.

Consequently, these procedures have required general anesthesia with TEE and fluoroscopic guidance. Initial procedures have taken a relatively long time (consistent with that for complex electrophysiology procedures), although procedure time has declined rapidly as individual operators and the team have gained experience. Initial single-clip cases have taken an average of 181 minutes compared with just over 2

hours for subsequent single-clip cases, which is frequently 70 to 90 minutes among the more experienced operators.

Important to the issue of the irreversibility of potentially ineffective percutaneous techniques, 17 (24%) of the initial 70 clip patients who subsequently required surgery have all had the intended surgical therapy, with repair accomplished in 71% of cases up to 18 months after clip placement.⁸⁶ However, surgical repair was not possible in 29% of patients in whom percutaneous repair was not successful because of either intraoperative anatomic findings (eg, leaflet defect) or preoperative considerations (eg, surgeon's preference).

The most prevalent clinical problem with the device, occurring in 5 cases, has been partial detachment of the clip from a single leaflet. This apparently results when the clips are not perpendicular to the line of leaflet coaptation at the time of placement, with relatively more tissue engaged in 1 of the 2 clip arms and less in the other. Clip detachment has been detected incidentally by surveillance echocardiograms and has not been associated with embolization or other clinical events.

Finally, relative to the issue discussed above of modifying target patient populations with less invasive techniques, it is important to consider that the median age of the EVEREST patients was 71 years (range, 26 to 88 years) compared with a median age of 59 years in the Society for Thoracic Surgery 2002 database for all mitral valve procedures. Fifty-one percent of the EVEREST patients have been in New York Heart Association class III or IV compared with 43% for patients undergoing surgical repair in the Society for Thoracic Surgery 2002 database.

EVEREST II, which randomizes clip device therapy with surgical mitral repair or replacement (2:1 randomization), may represent a potential model for subsequent percutaneous valve trial designs. The primary end point of the trial is noninferiority of the clip compared with surgery, defined as freedom from surgery for valve dysfunction, death, and moderate to severe or severe MR at 12 months. The primary safety end point is superiority in terms of freedom from major adverse events at 1 month. Whether alternative safety/efficacy end points would yield more relevant data and whether these devices should be compared with medical therapy in patients who are poor candidates for surgery or, on the other end of the spectrum, in patients with less severe MR who are not yet surgical candidates remain important points of debate.

Percutaneous Right Heart Valvular Procedures

Percutaneous pulmonary valve replacement actually represents the largest clinical experience to date in valve replacement. These procedures have been performed predominantly in patients with congenital heart disease and previous right ventricular outflow tract surgery. Most of the treated patients have had multiple prior surgical procedures, making percutaneous therapy especially attractive. Successful implantation of these devices has been reported in >160 patients with good hemodynamic results and low procedural risks, and a small number of patients have undergone retreatment with a percutaneous prosthesis successfully implanted within a previously percutaneously placed prosthesis.

The main limitation to right heart valve implants has been the lack of a variety of device sizes. A much wider selection of sizes

needs to be developed to treat young children and patients with dilated right ventricular outflow tracts. Optimal positioning of the devices also remains a challenge but is not as critical as for the aortic valve position; preprocedural imaging may assist in identifying the optimal position for deployment.

Finally, percutaneous tricuspid valve devices remain in the preclinical stages of development. Such devices could be deployed in the tricuspid annulus or in the superior and inferior vena cava, but tricuspid annular devices need to be correctly positioned to avoid obstruction of the coronary sinus ostium or damage to the atrioventricular node. An advantage of these devices is that they could be deployed under significantly lower time constraints than with other valve positions because right chamber pressures are lower and rapid pacing will not be required.

A disadvantage for the tricuspid valve devices is that tricuspid valve leaflets are more fragile than other valves and that damage to leaflet tissue may preclude subsequent conventional surgical repair. In addition, the tricuspid annulus lacks firm surrounding tissue for device placement and is frequently dilated in patients with tricuspid regurgitation. Percutaneous tricuspid valves also would not prevent further annular dilation and may therefore be susceptible to future dehiscence and/or embolization. The greatest limitations facing tricuspid valve therapies, however, are the disease-related factors in this population, including right ventricular failure and advanced pulmonary hypertension, rather than valve-related factors.

Final Considerations

As the populations of the United States and other industrialized countries continue to age, there appears to be little doubt that the need for less invasive and safer methods to treat valvular disease (particularly calcific AS) will continue to grow. It can be anticipated that after careful evaluations compared with contemporary treatment, there will also be a considerable impetus in the future for extending the use of new, less invasive techniques for treating valvular heart disease targeting high-risk patients today to other lower-risk patient groups.

In the context of the outstanding track record achieved for surgical AVR, for example, large trials with extremely large sample sizes will be required to prove equivalent hemodynamic and clinical results with new nonsurgical devices in "good" (low-risk) surgical candidates. These evaluations require close collaboration between interventional cardiologists, echocardiographers, engineers, and surgeons. Ideally, these practitioners and device manufacturers will support enrollment in appropriately powered, randomized, controlled trials. Although useful data can be accumulated in circumstances in which such trials are not possible (eg, critically ill patients in whom surgery is contraindicated), it will be important to be circumspect in extrapolating these data to lower-risk populations, given the excellent results achieved with surgical approaches.

If these steps are followed, it is probable that new interventional techniques will play an important role in the treatment of valve disease in the future. In view of the above discussions, the following focuses on the issues of greatest challenge, involving new percutaneous strategies, which need to be addressed in the development and maturation of less invasive valvular procedures.

Trial Design and Reporting of Results

The institution of appropriate trial designs and end points presents a significant challenge to the development of new valve treatment strategies. Issues such as appropriate selection of control groups and duration of follow-up will likely represent 2 of many potential areas of contention. For example, assuming that a standard for comparison in these trials should be whatever therapy a given patient would usually receive in most practices or hospitals, some percutaneous devices may be best suited for comparison with surgical valve replacement or repair, whereas others may require comparisons with medical therapy, as in heart failure populations with valvular disease. Moreover, the comparator for percutaneous mitral valve repair could be surgical valve repair for some patients and medical therapy for others. In other cases, the use of registries rather than randomized trials may be required, as in the case of high-risk or elderly patients. A multisociety review has recently addressed some of these issues,¹⁰⁰ but a greater consensus will likely need to evolve over time.

There has also been considerable debate regarding the investigator requirements necessary for centers to be involved in percutaneous valve trials. Ideally, centers will have excellence in both interventional cardiology and valve surgery. As clinical experiences expand, however, it is likely that more centers with less experience will be accrued as study sites, under which circumstances peer- and industry-sponsored mentoring and proctoring will likely be needed.

Standardization of what has thus far been fairly variable reporting practices will greatly enhance the development of this field. Some end points are relatively straightforward and should follow the guidelines developed for conventional valvular surgery, including structural valve deterioration, nonstructural valve dysfunction, endocarditis, thromboembolism, and bleeding events.⁹⁷ In addition, prospective evaluation of the severity of valvular insufficiency according to American Society of Echocardiography criteria and the use of core laboratories for echocardiography reading should be part of all new device trials.⁹⁸ In contrast, other parameters (eg, nature of pathophysiology and symptomatic compromise) are less well evolved and would benefit from reporting refinements.

Despite the existence of some reporting guidelines for such studies, it is clear that there is as yet no standard for the reporting of results for these procedures. For example, some first-in-human cases have been described as case reports; other technologies were not publicly reported until substantial data were accrued. One important report described the initial experience with the coronary sinus mitral annuloplasty device in which the first patients treated in the Canadian phase I experience had failed procedures.⁸⁶ This early description of suboptimal results is noteworthy in that it offers the investigative community the opportunity to resolve the cause of device failures, take corrective actions, and pursue appropriate clinical development pathways.

Procedure Team and Environment

As less invasive methodologies enter clinical practice, it can be anticipated that the traditional roles of cardiologists and cardiac surgeons will likely become less disparate over time. Such blurring of professional boundaries can already be

found in current clinical practice. Pacemaker implantation by cardiologists and aortic stent graft implantation by surgeons are 2 such examples. In this scenario, a convergence of subspecialty skills will likely occur, and increased collaboration will be required between cardiologists, cardiac surgeons, and interventional radiologists. Ideally, clinicians will need to become less territorial and more cooperative for percutaneous valvular techniques to develop and mature. Ideally, less attention will be placed on who "owns" the procedure and more focus will be put on the best interest of patients.

Alternative methods of reimbursement will be required in fee-for-service environments if real collaboration is to develop. In North America in particular, traditional medical versus surgical departmental structure and methods of reimbursement serve as a disincentive to cross-specialty collaboration. In addition, changes in specialty training will need to reflect the convergence of traditional roles. Cardiology fellowships may need to focus on vascular cutdown procedures and percutaneous ventricular support, and cardiac surgery fellowships may require training in catheterization techniques and balloon-stent management and troubleshooting.

Simulation technology is being used with increasing frequency for endovascular training and has already been developed for new investigators for percutaneous valve replacement. An obvious extension of this technology is to familiarize operators with the difficulties and complications frequently encountered by their surgical/medical colleagues. Standards for teaching and certification of operators will be challenging to develop and will require substantial further development in this field.

An important aspect of cross-specialty collaboration will be the choice of the optimal facility sites for less invasive valvular procedures. Clearly, many of these procedures require skills that are not routine in most catheterization laboratories or cardiac surgical suites. Prior experience with diagnostic and therapeutic percutaneous valve procedures, including transseptal skills, and experience with conventional valvular surgery are plainly requisite.

Most percutaneous procedures are currently performed in conventional catheterization laboratories, but the optimal environment for percutaneous valve procedures may well be a "hybrid" suite that is able to meet the demands of traditional cardiologic and surgical procedures. Hybrid suites will require ceiling-mounted mobile fluoroscopy and a control room, adequate infection control, sufficient space for TEE, a varied selection of surgical and catheterization equipment, cardiopulmonary bypass and ventricular support capability, and a complete anesthetic setup. CT, cardiac magnetic resonance, and 3-dimensional echocardiographic capabilities may need to be considered when these hybrid suites are built because these imaging modalities are likely to play a larger role in future less invasive valve procedures.

Procedural Considerations

Not surprisingly, a number of procedural challenges lie in the path of clinical adaptation of percutaneous valve therapies. Optimizing access routes will be a critical issue that will need to be addressed for percutaneous valve treatment strategies to become clinically applicable. Percutaneous aortic valves may

be deployed antegrade via the peripheral venous system and a transeptal puncture or retrograde via the femoral artery.

Antegrade valve delivery is difficult and technically complex and requires significant technical expertise because of limited device maneuverability. This approach has been complicated by acute mitral insufficiency during valve deployment. Retrograde valve delivery, although more direct and preferable at the current state of procedural development, is limited by femoral artery size, atherosclerosis and tortuosity of the aorta, and ability to traverse the stenotic native valve. Screening for atherosclerosis in the ascending aorta and arch by TEE, cardiac CT, or cardiac magnetic resonance is required. Patients with severely diseased iliofemoral systems or extreme tortuosity of the aorta will not be good candidates for this approach. Subclavian artery access has been used in some patients with inadequate iliofemoral access, whereas the degree of arch atheroma that precludes retrograde delivery is yet to be defined.

An alternative solution to peripheral access challenges may be found in transapical aortic valve deployment through a minithoracotomy incision. This can be performed without cardiopulmonary bypass, and it enables the use of larger device diameters with improved maneuverability, although at the cost of a surgical incision and local tissue trauma. Finally, although percutaneous access to the right-sided cardiac valves can be achieved through the peripheral venous system (femoral, jugular, or subclavian veins), and device size considerations are not as important as with left-sided devices, device maneuverability remains a significant challenge. Transapical device technology may therefore need to be extended to these valves in the future.

Percutaneous AVR device deployment is currently performed during rapid ventricular pacing to temporarily decrease cardiac output. However, rapid pacing is not infallible, and device embolization can still occur. In addition, the period of pacing must be short and device deployment must be rapid to avoid cerebral hypoperfusion. Other techniques may therefore be required to sustain cardiac output during device positioning and deployment. Options include cardiopulmonary bypass through peripheral (ie, femoral) access and percutaneous ventricular assist devices.

Another important issue is the use of distal aortic filters. Although aortic valve devices have been deployed without the use of filters thus far with a low risk of stroke, the development of embolic filter devices should be pursued to address this risk. Amongst alternative techniques, native valvular debridement or ablation before percutaneous valve insertion as a means to diminish embolization does not address embolization from the aorta. Leaflet decalcification also may adversely affect the calcified annular substrate preferred for anchoring stent-mounted devices.

The optimal imaging technique during percutaneous valve device deployment is another important consideration. Most current devices use a combination of fluoroscopy and TEE. Fluoroscopy is very helpful for anatomic localization in patients with calcified aortic valves. Fluoroscopy also is very good for anatomic localization in patients with failing tissue prostheses during so-called valve-in-valve procedures. The main limitations of fluoroscopy, however, are lack of detailed anatomic informa-

tion in patients without calcification and excessive equipment size, leading to interference with the operator's field.

TEE is required to delineate valvular morphology and pathology and to quantify valvular insufficiency and stenosis before and after the procedure. However, TEE is limited by device artifact and lack of detailed anatomic information. Three-dimensional TEE may play a future role in percutaneous valve therapy but is currently limited by time constraints for image reconstruction and suboptimal image quality. Intracardiac echocardiography also may have future applications, particularly for locating coronary artery ostia during aortic valve procedures. Future less invasive valve devices may be deployed with the use of real-time CT or cardiac magnetic resonance, and 3-dimensional digital "maps" may be constructed before the procedure to assist with accurate device implantation.

Device Considerations

Optimal percutaneous device design must be considered to be in the early stages of evolution. Current percutaneous valves are limited by the large vessel diameter required for valve loading and delivery, and minimization of the diameter is a significant objective for all devices. Current aortic valve devices encompass modifications of conventional biological valves, rather than mechanical prostheses, because of their ability to be compressed into a sheath without significantly compromising function. Although biological valves also have the advantage of avoiding long-term anticoagulation and have yielded favorable durability as surgical implants, the long-term durability of percutaneous valves, which have incorporated bovine jugular venous, equine pericardial, and bovine pericardial valve tissue, is unknown. Compressible nitinol valves are in the very early stages of development but may represent a novel percutaneous treatment strategy in the future.

As noted in the discussion of percutaneous AVR above, stent and cuff designs also are important considerations for percutaneous valves. Stents need to be large enough for secure positioning but small enough to be deployed through transvascular sheaths. The optimal stent material should cause minimal imaging artifact on echocardiography and CT and should be compatible with cardiac magnetic resonance. It should also possess long-term durability in the face of repeated movement and hemodynamic stress. Valve cuffs need to be tall enough to prevent paravalvular leaks but short enough to prevent obstruction of nearby vital structures (eg, coronary ostia for the aortic valve position). The optimal cuff material will be one that prevents paravalvular blood flow but does not lead to excessive tissue ingrowth or pannus formation.

A final consideration in the development of less invasive valve devices is their effect on future therapeutic interventions. This issue will be particularly important as clinical studies move from elderly, high-risk, nonsurgical candidates to young, low-risk patients. Mitral and tricuspid regurgitation devices specifically should be removable at the time of initial implantation in the case of procedural or device failure without compromising the ability of conventional surgical valve repair.

The clip device has been removed from patients as late as 18 months after placement without limiting surgical repair,¹⁰⁰ but eventually there will be a point at which the clip cannot be removed during subsequent surgical procedures. Aortic and

pulmonary valve devices also will not be easily removable in the case of long-term subsequent deterioration and may require the development of novel repeat procedural approaches.

Bailout options in case of improper acute device deployment are a last consideration. To a certain extent, most current devices can be removed completely if there are concerns about lack of efficacy or safety. Future percutaneous valve replacement devices should allow operators to easily retrieve or reposition an improperly deployed device without damaging vascular and surrounding tissues.

Conclusions and Recommendations

Minimally invasive surgical and percutaneous valve techniques will likely become the predominant means of treating critical valve disease, although the course of development will take years. A broad transition of surgical therapy to minimally invasive (robotic, PORT ACCESS, or minithoracotomy) approaches can be anticipated and is encouraged on the basis of most recent experiences in a growing number of centers. Initial experience with percutaneous devices has already demonstrated proof of concept and yielded intriguing data. Percutaneous valve therapy devices and techniques require significant modification before widespread clinical use can be adopted and require evaluation in clinical trials under careful investigational protocols. Randomized comparisons with existing standard of care

treatments and registries for high-risk patients will define the roles of these new technologies. These trials should be performed with the collaboration of cardiologists and cardiac surgeons in centers with excellent surgical and catheter experience and a commitment to trial participation. For the near term, percutaneous techniques in central and percutaneous AVR in particular remain investigational and should be limited in use to patients considered to be high risk or to inoperable surgical candidates. In this context, even after FDA approvals, percutaneous devices should be used in only a small number of centers with excellent surgical and catheter experience until they are thoroughly tested in the clinical arena.

To actualize these transitions, numerous challenges in trial design are being addressed.^{101,102} The definitions of patients who are appropriate candidates for these new approaches also will need to evolve. Significant refinement of the traditional training, roles, and routines of cardiologists and surgeons will be required in the acceptance and widespread implementation of these novel strategies, and close collaboration among disciplines will be needed for successful programmatic development. Ongoing attention to these important issues regarding patients, devices, and operators should stimulate the necessary changes to make less invasive valve therapies a viable option for the future treatment of valvular heart disease.

Disclosures

Writing Group Disclosures

Writing Group Member	Employment	Research Grant	Other Research Support	Speakers' Bureau/Honoraria	Ownership Interest	Consultant/Advisory Board	Other
Todd K. Rosengart	State University of New York–Stony Brook	American Heart Association*	None	None	MDX†	EMMI*	Myocor*
Robert O. Bonow	Northwestern University	None	None	None	None	Edwards LifeSciences*	None
Michael A. Borger	Leipzig Heart Center	None	None	Edwards LifeSciences*; Medtronic*	None	None	None
Ted Feldman	Evanston Northwestern Healthcare	Cardiac Dimensions; Evalve*	None	None	None	Cardiac Dimensions*; Myocor*	None
A. Marc Gillinov	Cleveland Clinic Foundation	None	Edwards LifeSciences†; St Jude*	Edwards LifeSciences†; Medtronic*	Viacor, Inc†	Edwards LifeSciences†	None
Katherine J. Hoercher	Cleveland Clinic Foundation	None	None	None	None	None	None
William O'Neill	University of Miami	None	None	None	None	None	None
Alec Vahanian	Bichat Hospital, Paris, France	None	Edwards LifeSciences*	Edwards LifeSciences*	None	Edwards LifeSciences*; CoreValue*	None
Thomas A. Vassiliades, Jr	Emory University	Evalve*; Myocor*	None	None	CorSynergy Inc†	Guidant Corp*; Boston Scientific*	None

This table represents the relationships of writing group members that may be perceived as actual or reasonably perceived conflicts of interest as reported on the Disclosure Questionnaire, which all members of the writing group are required to complete and submit. A relationship is considered to be "significant" if (a) the person receives \$10 000 or more during any 12-month period, or 5% or more of the person's gross income; or (b) the person owns 5% or more of the voting stock or share of the entity, or owns \$10 000 or more of the fair market value of the entity. A relationship is considered to be "modest" if it is less than "significant" under the preceding definition.

*Modest.

†Significant.

Reviewer Disclosures

Reviewer	Employment	Research Grant	Other Research Support	Speakers' Bureau/Honoraria	Expert Witness	Ownership Interest	Consultant/Advisory Board	Other
Eugene A. Grossi	New York University Medical Center	None	None	None	None	None	None	None
Eberhard Grube	Helios Heart Center Sieeburg	None	None	None	None	None	None	None
Loren F. Hiratzka	Bethesda North Hospital	None	None	None	None	None	None	None

This table represents the relationships of reviewers that may be perceived as actual or reasonably perceived conflicts of interest as reported on the Disclosure Questionnaire, which all reviewers are required to complete and submit.

References

- Nkomo VT, Gardin JM, Skelton TN, Gottdiener JS, Scott CG, Enrique-Sarano M. Burden of valvular heart disease: a population-based study. *Lancet*. 2006;368:1005–1011.
- Iung B, Baron G, Butchart EG, Delahaye F, Gohlke-Bärwolf C, Levang OW, Tornos P, Vanoverschelde JL, Vermeer F, Boersma E, Ravaut P, Vahanian A. A prospective survey of patients with valvular heart disease in Europe: the Euro Heart Survey on Valvular Heart Disease. *Eur Heart J*. 2003;24:1231–1243.
- Inoue K, Owaki T, Nakamura T, Kitamura F, Miyamoto N. Clinical application of transvenous mitral commissurotomy by a new balloon catheter. *J Thorac Cardiovasc Surg*. 1984;87:394–402.
- Feldman T, Herrmann HC, Inoue K. Technique of percutaneous transvenous mitral commissurotomy using the Inoue balloon catheter. *Cathet Cardiovasc Diagn*. 1994;(suppl 2):26–34.
- Vahanian A, Palacios IF. Percutaneous approaches to valvular disease. *Circulation*. 2004;109:1572–1579.
- STS national database: STS U.S. cardiac surgery database: 1997 aortic valve replacement patients: preoperative risk variables. Chicago, Ill: Society of Thoracic Surgeons; 2000. Available at: <http://www.ctsnet.org/doc/3031>. Accessed May 10, 2006.
- Astor BC, Kaczmarek Hefflin B, Daley MR. Mortality after aortic valve replacement: results from a nationally representative database. *Ann Thorac Surg*. 2000;70:1939–1945.
- Gogbashian A, Sepic J, Soltesz EJ, Nascimben L, Cohn LH. Operative and long-term survival of elderly is significantly improved by mitral valve repair. *Am Heart J*. 2006;151:1325–1333.
- Lee P, Germann E, Jamieson WR, Nicholson PJ, Fradjet GJ, Miyagishimi RT. Mitral valve reconstruction: experience related to early and late mortality and reoperation. *J Heart Valve Dis*. 2005;14:715–721.
- Iung B, Cachier A, Baron G, Messika-Zeitoun D, Delahaye F, Tornos P, Gohlke-Barwolf C, Boersma E, Ravaut P, Vahanian A. Decision-making in elderly patients with severe aortic stenosis: why are so many denied surgery? *Eur Heart J*. 2005;26:2714–2720.
- Varadarajan P, Kapoor N, Bansal RC, Pai RG. Clinical profile and natural history of 453 nonsurgically managed patients with severe aortic stenosis. *Ann Thorac Surg*. 2006;82:2111–2115.
- Bonow RO, Carabello BA, Kanu C, de Leon AC Jr, Faxon DP, Freed MD, Gaasch WH, Lytle BW, Nishimura RA, O'Gara PT, O'Rourke RA, Otto CM, Shah PM, Shanewise JS, Smith SC Jr, Jacobs AK, Adams CD, Anderson JL, Antman EM, Faxon DP, Fuster V, Halperin JL, Hiratzka LF, Hunt SA, Lytle BW, Nishimura R, Page RL, Riegel B. ACC/AHA 2006 guidelines for the management of patients with valvular heart disease: a report of the American College of Cardiology/American Heart Association Task Force on Practice Guidelines (Writing Committee to Revise the 1998 Guidelines for the Management of Patients With Valvular Heart Disease). *Circulation*. 2006;114:e84–e231.
- Society of Thoracic Surgeons National Database. Available at: <http://www.sts.org>. Accessed December 1, 2006.
- Lytle BW, Cosgrove DM, Taylor PC, Goormastic M, Stewart RW, Golding LA, Gill CC, Loop FD. Primary isolated aortic valve replacement: early and late results. *J Thorac Cardiovasc Surg*. 1989;97:675–694.
- Chiappini B, Camurri N, Loforte A, Di Marco L, Di Bartolomeo R, Marinelli G. Outcome after aortic valve replacement in octogenarians. *Ann Thorac Surg*. 2004;78:85–89.
- Kvidal P, Bergstrom R, Horte L-G, Stahle E. Observed and relative survival after aortic valve replacement. *J Am Coll Cardiol*. 2000;35:747–756.
- Edwards FH, Peterson ED, Coombs LP, DeLong ER, Jamieson RE, Shroyer ALW, Grover FL. Prediction of operative mortality after valve replacement surgery. *J Am Coll Cardiol*. 2001;37:885–892.
- Edwards MB, Taylor KM. Outcomes in nonagenarians after heart valve replacement operation. *Ann Thorac Surg*. 2003;75:830–834.
- Jamieson WRE, Edwards FH, Schwartz M, Bero JW, Clark RE, Grover FL. Risk stratification for cardiac valve replacement: National Cardiac Surgery Database: Database Committee of the Society of Thoracic Surgeons. *Ann Thorac Surg*. 1999;67:943–951.
- Scott WC, Miller DC, Haverich A, Dawkins K, Mitchell RS, Jamieson SW, Oyer PE, Stinson EB, Baldwin JC, Shumway NE. Determinants of operative mortality for patients undergoing aortic valve replacement: discriminant analysis of 1,479 operations. *J Thorac Cardiovasc Surg*. 1985;89:400–413.
- Deleted in proof.
- Byrne JG, Karavas AN, Cohn LH, Adams DH. Minimal access aortic root, valve, and complex ascending aortic surgery. *Curr Cardiol Rep*. 2000;2:549–557.
- Walther T, Falk V, Mohr FW. Minimally invasive surgery for valve disease. *Curr Probl Cardiol*. 2006;31:399–437.
- Sharony R, Grossi EA, Saunders PC, Schwartz CF, Ribakove GH, Culliford AT, Ursomanno P, Baumann FG, Galloway AC, Clavin SB. Minimally invasive aortic valve surgery in the elderly: a case-control study. *Circulation*. 2003;108(suppl II):II-43–II-47.
- Minale C, Tomasco B, Di Natale M. A cosmetic access for minimally invasive aortic valve replacement without sternotomy in women. *Ital Heart J*. 2002;3:473–475.
- Detter C, Deuse T, Boehm DH, Reichenspurner H, Reichart B. Midterm results and quality of life after minimally invasive vs. conventional aortic valve replacement. *Thorac Cardiovasc Surg*. 2002;50:337–341.
- Masiello P, Coscioni E, Panza A, Triumbari F, Preziosi G, Di Benedetto G. Surgical results of aortic valve replacement via partial upper sternotomy: comparison with median sternotomy. *Cardiovasc Surg*. 2002;10:333–338.
- Autschbach R, Walther T, Falk V, Diegeler A, Metz S, Mohr FW. S-shaped in comparison to L-shaped partial sternotomy for less invasive aortic valve replacement. *Eur J Cardiothorac Surg*. 1998;14(suppl I):S117–S121.
- Gillinov AM, Banbury MK, Cosgrove DM. Hemisternotomy approach for aortic and mitral valve surgery. *J Card Surg*. 2000;15:15–20.
- Bakir I, Casselman FP, Wellens F, Jeanmart H, De Geest R, Degrieck I, Van Praet F, Vermeulen Y, Vanermen H. Minimally invasive versus standard approach aortic valve replacement: a study in 506 patients. *Ann Thorac Surg*. 2006;81:1599–1604.
- Walther T, Falk V, Metz S, Diegeler A, Battellini R, Autschbach R, Mohr FW. Pain and quality of life after minimally invasive versus conventional cardiac surgery. *Ann Thorac Surg*. 1999;67:1643–1647.
- Sharony R, Grossi EA, Saunders PC, Schwartz CF, Ribakove GH, Baumann FG, Galloway AC, Clavin SB. Propensity score analysis of a six-year experience with minimally invasive isolated aortic valve replacement. *J Heart Valve Dis*. 2004;13:887–893.
- Candaele S, Herijgers P, Demeyere R, Flameng W, Evers G. Chest pain after partial upper versus complete sternotomy for aortic valve surgery. *Acta Cardiol*. 2003;58:17–21.
- Stamou SC, Kapetanakis EI, Lowery R, Jablonski KA, Frankel TL, Corso PJ. Allogenic blood transfusion requirements after minimally invasive versus conventional aortic valve replacement: a risk-adjusted analysis. *Ann Thorac Surg*. 2003;76:1101–1106.
- Vanoverbeke H, Van Belleghem Y, Francois K, Caes F, Bove T, Van Nooten G. Operative outcome of minimal access aortic valve

- replacement versus standard procedure. *Acta Chir Belg.* 2004;104:440–444.
36. De Smet JM, Rondelet B, Jansens JL, Antoine M, De Canniere D, Le Clerc JL. Assessment based on EuroSCORE of ministernotomy for aortic valve replacement. *Asian Cardiovasc Thorac Ann.* 2004;12:53–57.
 37. Farhat F, Lu Z, Lefevre M, Montagna P, Mikaeloff P, Jegaden O. Prospective comparison between total sternotomy and ministernotomy for aortic valve replacement. *J Card Surg.* 2003;18:396–401.
 38. Walther T, Dewey T, Wimmer-Greinecker G, Doss M, Hambrecht R, Schuler G, Mohr FW, Mack M. Transapical approach for sutureless stent-fixed aortic valve implantation: experimental results. *Eur J Cardiothorac Surg.* 2006;29:703–708.
 39. Huber CH, Cohn LH, von Segesser LK. Direct-access valve replacement: a novel approach for off-pump valve implantation using valved stents. *J Am Coll Cardiol.* 2005;46:366–370.
 40. Huber CH, von Segesser LK. Direct access valve replacement (DAVR): are we entering a new era in cardiac surgery? *Eur J Cardiothorac Surg.* 2006;29:380–385.
 41. Walther T, Falk V, Borger MA, Dewey T, Wimmer-Greinecker G, Schuler G, Mack M, Mohr FW. Minimally invasive transapical beating heart aortic valve implantation: proof of concept. *Eur J Cardiothorac Surg.* 2006;31:9–15.
 42. Lichtenstein SV, Cheung A, Ye J, Thompson CP, Carere RG, Pasupati S, Webb JG. Transapical transcatheter aortic valve implantation in humans: initial clinical experience. *Circulation.* 2006;114:591–596.
 43. Lichtenstein SV. Closed heart surgery: back to the future. *J Thorac Cardiovasc Surg.* 2006;131:941–943.
 44. Gammie JS, Brown JW, Brown JM, Poston RS, Pierson RN 3rd, Odonkor PN, White CS, Gottdiener JS, Griffith BP. Aortic valve bypass for aortic stenosis. *Ann Thorac Surg.* 2006;81:1605–1610.
 45. Vassiliades TA Jr. Off-pump apicoaortic conduit insertion for high-risk patients with aortic stenosis. *Eur J Cardiothorac Surg.* 2003;23:156–158.
 46. Salas J, De Vega NG, De Rabago G. Apicoaortic conduit implanted without cardiopulmonary bypass: a useful contingency technique. *J Cardiovasc Surg (Torino).* 1989;30:798–800.
 47. Cooley DA, Lopez RM, Absi S. Apicoaortic conduit for left ventricular outflow tract obstruction: revisited. *Ann Thorac Surg.* 2000;69:1511–1514.
 48. Renzulli A, Gregorio R, De Feo M, Ismeno G, Covino FE, Cotrufo M. Long-term results of apico-aortic valved conduit for severe idiopathic hypertrophic subaortic stenosis. *Tex Heart Inst J.* 2000;27:24–28.
 49. Puvimanasinghe JP, Takkenberg JJ, Eijkemans MJ, van Herweden LA, Jamieson WR, Grunkemeier GL, Habbema JD, Bogers AJ. Comparison of Carpentier-Edwards pericardial and supraannular bioprosthesis in aortic valve replacement. *Eur Cardiothorac Surg.* 2006;29:374–379.
 50. O'Neill WW. Predictors of long-term survival after percutaneous aortic valvuloplasty: report of the Mansfield Scientific Balloon Aortic Valvuloplasty Registry. *J Am Coll Cardiol.* 1991;17:193–198.
 51. Pedersen WR, Van Tassel TA, Pierce TA, Pence DM, Monyak DJ, Kim TH, Harris KM, Knickelbine T, Lesser JR, Madison JD, Mooney MR, Goldenberg IF, Longe TF, Poulouse AK, Graham KJ, Nelson RR, Pritzker MR, Pagan-Carlo LA, Boisjolie CR, Zenovich AG, Schwartz RS. Radiation following percutaneous balloon aortic valvuloplasty to prevent restenosis (RADAR pilot trial). *Catheter Cardiovasc Interv.* 2006;68:183–102.
 52. Cribier A, Eltchaninoff H, Tron C. First human transcatheter implantation of an aortic valve prosthesis in a case of severe calcific aortic stenosis [in French]. *Ann Cardiol Angeiol (Paris).* 2003;52:173–175.
 53. Hanzel GS, Harry PJ, Schreiber TL, O'Neill WW. Retrograde percutaneous aortic valve implantation for critical aortic stenosis. *Catheter Cardiovasc Interv.* 2005;64:322–326.
 54. Webb JG, Chandavimol M, Thompson CR, Ricci DR, Carere RG, Munt BI, Buller CE, Pasupati S, Lichtenstein S. Percutaneous aortic valve implantation retrograde from the femoral artery. *Circulation.* 2006;113:842–850.
 55. Grube E, Laborde JC, Gerckens U, Felderhoff T, Sauren B, Buellesfeld L, Mueller R, Menicelli M, Schmidt T, Zickmann B, Iversen S, Stone GW. Percutaneous implantation of the CoreValve self-expanding valve prosthesis in high-risk patients with aortic valve disease: the Siegburg first-in-man study. *Circulation.* 2006;114:1616–1624.
 56. Hanzel GS, O'Neill WW. Complications of percutaneous aortic valve replacement: experience with the Cribier-EdwardTM percutaneous heart valve. *EuroIntervention.* 2006;1:A3–A8.
 57. Cohn LH, Adams DH, Couper GS, Bichell DP, Rosborough DM, Sears SP, Aranki SF. Minimally invasive cardiac valve surgery improves patient satisfaction while reducing costs of cardiac valve replacement and repair. *Ann Surg.* 1997;226:421–426.
 58. Mihaljevic T, Cohn LH, Unic D, Aranki SF, Couper GS, Byrne JG. One thousand minimally invasive valve operations: early and late results. *Ann Surg.* 2004;240:529–534.
 59. Grossi EA, Galloway AC, Ribakove GH, Zakow PK, Derivaux CC, Baumann FG, Schwesinger D, Colvin SB. Impact of minimally invasive valvular heart surgery: a case-control study. *Ann Thorac Surg.* 2001;71:807–810.
 60. Cosgrove DM 3rd, Sabik JF, Navia JL. Minimally invasive valve operations. *Ann Thorac Surg.* 1998;65:1535–1538.
 61. Aklog L, Adams DH, Couper GS, Gobeze R, Sears S, Cohn LH. Techniques and results of direct-access minimally invasive mitral valve surgery: a paradigm for the future. *J Thorac Cardiovasc Surg.* 1998;116:705–715.
 62. Gillinov AM, Cosgrove DM. Minimally invasive mitral valve surgery: mini-sternotomy with extended transeptal approach. *Semin Thorac Cardiovasc Surg.* 1999;11:206–211.
 63. Deleted in proof.
 64. Carpentier A, Loulmet D, Carpentier A, Le Bret E, Haugades B, Dassier P, Guibourt P. Open heart operation under videosurgery and minithoracotomy: first case (mitral valvuloplasty) operated with success [in French]. *C R Acad Sci III.* 1996;319:219–223.
 65. Grossi EA, Galloway AC, LaPietra A, Ribakove GH, Ursomanno P, Delianides J, Culliford AT, Bizakis C, Esposito RA, Baumann FG, Kanchuger MS, Colvin SB. Minimally invasive mitral valve surgery: a 6-year experience with 714 patients. *Ann Thorac Surg.* 2002;74:660–663.
 66. Deleted in proof.
 67. Galloway AC, Shemin RJ, Glower DD, Boyer JH Jr, Groh MA, Kuntz RE, Burdon TA, Ribakove GH, Reitz BA, Colvin SB. First report of the Port Access International Registry. *Ann Thorac Surg.* 1999;67:51–56.
 68. Glower DD, Siegel LC, Frischmeyer KJ, Galloway AC, Ribakove GH, Grossi EA, Robinson NB, Ryan WH, Colvin SB. Predictors of outcome in a multicenter port-access valve registry. *Ann Thorac Surg.* 2000;70:1054–1059.
 69. Mohr FW, Falk V, Diegeler A, Walther T, van Son JA, Autschbach R. Minimally invasive port-access mitral valve surgery. *J Thorac Cardiovasc Surg.* 1998;115:567–576.
 70. Falk V, Walther T, Autschbach R, Diegeler A, Battellini R, Mohr FW. Robot-assisted minimally invasive solo mitral valve operation. *J Thorac Cardiovasc Surg.* 1998;115:470–471.
 71. Nifong LW, Chitwood WR, Pappas PS, Smith CR, Argenziano M, Starnes VA, Shah PM. Robotic mitral valve surgery: a United States multicenter trial. *J Thorac Cardiovasc Surg.* 2005;129:1395–1404.
 72. Nifong LW, Chu VF, Bailey M, Maziarz DM, Sorrell VL, Holbert D, Chitwood WR Jr. Robotic mitral valve repair: experience with the da Vinci system. *Ann Thorac Surg.* 2003;75:438–442.
 73. Tatooles AJ, Pappas PS, Gordon PJ, Slaughter MS. Minimally invasive mitral valve repair using the da Vinci robotic system. *Ann Thorac Surg.* 2004;77:1978–1984.
 74. Chitwood WR Jr, Elbeery JR, Chapman WH, Moran JM, Lust RL, Wooden WA, Deaton DH. Video-assisted minimally invasive mitral valve surgery: the “micro-mitral” operation. *J Thorac Cardiovasc Surg.* 1997;113:413–414.
 75. Aybek T, Dogan S, Risteski PS, Zierer A, Wittlinger T, Wimmer-Greinecker G, Moritz A. Two hundred forty minimally invasive mitral operations through right minithoracotomy. *Ann Thorac Surg.* 2006;81:1618–1624.
 76. Reichenspurner H, Detter C, Deuse T, Boehm DH, Treede H, Reichart B. Video and robotic-assisted minimally invasive mitral valve surgery: a comparison of the Port-Access and transthoracic clamp techniques. *Ann Thorac Surg.* 2005;79:485–491.
 77. Fucci C, Sandrelli L, Pardini A, Torracca L, Ferrari M, Alfieri O. Improved results with mitral valve repair using new surgical techniques. *Eur J Cardiothorac Surg.* 1995;9:621–626.
 78. Alfieri O, Maisano F, De Bonis M, Stefano PL, Torracca L, Oppizzi M, La Canna G. The double-orifice technique in mitral valve repair: a simple solution for complex problems. *J Thorac Cardiovasc Surg.* 2001;122:674–681.
 79. Maisano F, Caldarola A, Blasio A, De Bonis M, La Canna G, Alfieri O. Midterm results of edge-to-edge mitral valve repair without annuloplasty. *J Thorac Cardiovasc Surg.* 2003;126:1987–1997.

80. Maisano F, Vigano B, Blasio A, Colombo A, Calabrese C, Alfieri O. Surgical isolated edge-to-edge mitral repair without annuloplasty: clinical proof of principle for an endovascular approach. *EuroIntervention*. 2006;21:181–186.
81. Feldman T, Herrmann HC, St Goar F. Percutaneous treatment of valvular heart disease: catheter-based aortic valve replacement and mitral valve repair therapies. *Am J Geriatr Cardiol*. 2006;15:291–301.
82. Fann JI, St Goar FG, Komtebedde J, Oz MC, Block PC, Foster E, Feldman T, Burdon TA. Off-pump edge-to-edge mitral valve technique using a mechanical clip in a chronic model. *Circulation*. 2003;108(suppl IV):IV-493. Abstract.
83. Bhudia SK, McCarthy PM, Smedira NG, Lam BK, Rajeswaran J, Blackstone EH. Edge-to-edge mitral valve repair (Alfieri) mitral repair: results in diverse clinical settings. *Ann Thorac Surg*. 2004;77:1598–1606.
84. Mani CV, Patel JB, Reuter DG, Meyer DM, Edwards WD, Rihal CS, Redfield MM. Acute and chronic reduction of functional mitral regurgitation in experimental heart failure by percutaneous mitral annuloplasty. *J Am Coll Cardiol*. 2004;44:1652–1661.
85. Byrne MJ, Kaye DM, Mathis M, Reuter DG, Alfernese CA, Power JM. Percutaneous mitral annular reduction provides continued benefit in an ovine model of dilated cardiomyopathy. *Circulation*. 2004;110:3088–3092.
86. Webb JG, Harnek J, Munt BI, Kimblad PO, Chandavimol M, Thompson CR, Mayo JR, Solem JO. Percutaneous transvenous mitral annuloplasty: initial human experience with device implantation in the coronary sinus. *Circulation*. 2006;113:851–855.
87. Liddicoat JR, Mac Neill BD, Gillinov AM, Cohn WE, Chin CH, Prado AD, Pandian NG, Oesterle SN. Percutaneous mitral valve repair: a feasibility study in an ovine model of acute ischemic mitral regurgitation. *Catheter Cardiovasc Interv*. 2003;60:410–416.
88. Oesterle SN, Gillinov AM, Chin CH, Xing YQ, Prado AD, Pandian NG. Percutaneous catheter-based mitral valve repair. *J Am Coll Cardiol*. 2002;39(suppl 2):432. Abstract.
89. Tibayan FA, Rodriguez F, Liang D, Daughters GT, Ingels NB Jr, Miller DC. Paneth suture annuloplasty abolishes acute ischemic mitral regurgitation but preserves annular and leaflet dynamics. *Circulation*. 2003;108(suppl II):II-128–II-133.
90. Aybek T, Risteski P, Miskovic A, Simon A, Dogan S, Abdel-Rahman U, Moritz A. Seven years' experience with suture anuloplasty for mitral valve repair. *J Thorac Cardiovasc Surg*. 2006;131:99–106.
91. Grossi EA, Saunders PC, Woo J, Gangahar DM, Laschinger JC, Kress DC, Caskey MP, Schwartz CF, Wudel J. Intraoperative effects of the Coapsys annuloplasty system in a randomized evaluation (RESTOR-MV) of functional ischemic mitral regurgitation. *Ann Thorac Surg*. 2005;80:1706–1711.
92. Mishra YK, Mittal S, Jaguri P, Trehan N. Coapsys mitral annuloplasty for chronic functional ischemic mitral regurgitation: 1-year results. *Ann Thorac Surg*. 2006;81:42–46.
93. Rogers JH, Macoviak JA, Rahdert DA, Takeda PA, Palacios IF, Low RI. Percutaneous septal sinus shortening: a novel procedure for the treatment of functional mitral regurgitation. *Circulation*. 2006;113:2329–2334.
94. Feldman T, Wasserman HS, Herrmann HC, Gray W, Block PC, Whitlow P, St Goar F, Rodriguez L, Silvestry F, Schwartz A, Sanborn TA, Condado JA, Foster E. Percutaneous mitral valve repair using the edge-to-edge technique: six-month results of the EVEREST phase I clinical trial. *J Am Coll Cardiol*. 2005;46:2134–2140.
95. Feldman T, Wasserman HS, Herrmann HC, Whitlow PL, Block PC, Gray WA, Foster E, St Goar F. Edge-to-edge mitral valve repair using the Evalve MitraClip: one year results of the EVEREST phase I clinical trial. *Am J Cardiol*. 2005;96(suppl 7A):49H. Abstract.
96. Herrmann HC, Wasserman HS, Whitlow PL, Block PC, Gray WA, Rohatgi S, Foster E, St Goar F, Feldman T. Percutaneous edge-to-edge mitral valve repair using the Evalve Mitraclip: initial one year results of the EVEREST phase I clinical trial. *Circulation*. 2005;112(suppl II):II-520. Abstract.
97. Bonow RO, Carabello B, de Leon AC Jr, Edmunds LH Jr, Fedderly BJ, Freed MD, Gaasch WH, McKay CR, Nishimura RA, O'Gara PT, O'Rourke RA, Rahimtoola SH, Ritchie JL, Cheitlin MD, Eagle KA, Gardner TJ, Garson A Jr, Gibbons RJ, Russell RO, Ryan TJ, Smith SC Jr. Guidelines for the management of patients with valvular heart disease: executive summary: a report of the American College of Cardiology/American Heart Association Task Force on Practice Guidelines (Committee on Management of Patients with Valvular Heart Disease). *Circulation*. 1998;98:1949–1984.
98. Zoghbi WA, Enriquez-Sarano M, Foster E, Grayburn PA, Kraft CD, Levine RA, Nihoyannopoulos P, Otto CM, Quinones MA, Rakowski H, Stewart WJ, Waggoner A, Weissman NJ, for the American Society of Echocardiography. Recommendations for evaluation of the severity of native valvular regurgitation with two-dimensional and Doppler echocardiography. *J Am Soc Echocardiogr*. 2003;16:777–802.
99. Deleted in proof.
100. Dang NC, Aboodi MS, Sakaguchi T, Wasserman HS, Argenziano M, Cosgrove DM, Rosengart TK, Feldman T, Block PC, Oz MC. Surgical revision after percutaneous mitral valve repair with a clip: initial multicenter experience. *Ann Thorac Surg*. 2005;80:2338–2342.
101. Vassiliades TA Jr, Block PC, Cohn LH, Adams DH, Borer JS, Feldman T, Holmes DR, Laskey WK, Lytle BW, Mack MJ, Williams DO. The clinical development of percutaneous heart valve technology: a position statement of the Society of Thoracic Surgeons (STS), the American Association for Thoracic Surgery (AATS), and the Society of Cardiovascular Angiography and Intervention (SCAI). *J Thorac Cardiovasc Surg*. 2005;129:970–976.
102. Feldman T. Percutaneous valve repair and replacement: challenges encountered, challenges met, challenges ahead. *Circulation*. 2006;113:771–773.

Percutaneous and Minimally Invasive Valve Procedures: A Scientific Statement From the American Heart Association Council on Cardiovascular Surgery and Anesthesia, Council on Clinical Cardiology, Functional Genomics and Translational Biology Interdisciplinary Working Group, and Quality of Care and Outcomes Research Interdisciplinary Working Group

Todd K. Rosengart, Ted Feldman, Michael A. Borger, Thomas A. Vassiliades, Jr, A. Marc Gillinov, Katherine J. Hoercher, Alec Vahanian, Robert O. Bonow and William O'Neill

Circulation. 2008;117:1750-1767; originally published online March 10, 2008;
doi: 10.1161/CIRCULATIONAHA.107.188525

Circulation is published by the American Heart Association, 7272 Greenville Avenue, Dallas, TX 75231
Copyright © 2008 American Heart Association, Inc. All rights reserved.
Print ISSN: 0009-7322. Online ISSN: 1524-4539

The online version of this article, along with updated information and services, is located on the
World Wide Web at:

<http://circ.ahajournals.org/content/117/13/1750>

Permissions: Requests for permissions to reproduce figures, tables, or portions of articles originally published in *Circulation* can be obtained via RightsLink, a service of the Copyright Clearance Center, not the Editorial Office. Once the online version of the published article for which permission is being requested is located, click Request Permissions in the middle column of the Web page under Services. Further information about this process is available in the [Permissions and Rights Question and Answer](#) document.

Reprints: Information about reprints can be found online at:
<http://www.lww.com/reprints>

Subscriptions: Information about subscribing to *Circulation* is online at:
<http://circ.ahajournals.org/subscriptions/>