Short QT Syndrome
A Familial Cause of Sudden Death

Fiorenzo Gaita, MD; Carla Giustetto, MD; Francesca Bianchi, MD; Christian Wolpert, MD; Rainer Schimpf, MD; Riccardo Riccardi, MD; Stefano Grossi, MD; Elena Richiardi, MD; Martin Borggrefe, MD

Background—A prolonged QT interval is associated with a risk for life-threatening events. However, little is known about prognostic implications of the reverse—a short QT interval. Several members of 2 different families were referred for syncope, palpitations, and resuscitated cardiac arrest in the presence of a positive family history for sudden cardiac death. Autopsy did not reveal any structural heart disease. All patients had a constantly and uniformly short QT interval at ECG.

Methods and Results—Six patients from both families were submitted to extensive noninvasive and invasive work-up, including serial resting ECGs, echocardiogram, cardiac MRI, exercise testing, Holter ECG, and signal-averaged ECG. Four of 6 patients underwent electrophysiological evaluation including programmed ventricular stimulation. In all subjects, a structural heart disease was excluded. At baseline ECG, all patients exhibited a QT interval ≤280 ms (QTc ≤300 ms). During electrophysiological study, short atrial and ventricular refractory periods were documented in all and increased ventricular vulnerability to fibrillation in 3 of 4 patients.

Conclusions—The short QT syndrome is characterized by familial sudden death, short refractory periods, and inducible ventricular fibrillation. It is important to recognize this ECG pattern because it is related to a high risk of sudden death in young, otherwise healthy subjects. **(*Circulation*. 2003;108:965-970.)**

Key Words: short QT interval ■ death, sudden ■ fibrillation

Downloaded from http://circ.ahajournals.org/ by guest on March 22, 2017

Ventricular fibrillation is the main mechanism involved in sudden cardiac death. The vast majority of patients present with a manifest structural cardiac disease; however, in a small percentage of patients, an underlying cardiac abnormality cannot be identified and ventricular fibrillation is termed "idiopathic." Some syndromes have been described in recent years[1–5] and limited the cases of unexplained ventricular fibrillation. Even if sudden death in the absence of heart disease is a rare event, its clinical impact is high because it often occurs in young and otherwise healthy subjects. It is desirable that other clinical/ECG entities be identified in the future to further elucidate underlying electrical abnormalities in the so-called idiopathic fibrillation patients.

The QT interval represents ventricular repolarization. It is well known that a prolonged QT interval is associated with an increased risk of life-threatening ventricular arrhythmias, and several reports have defined the upper limits of normality for heart rate–corrected QT interval. Conversely, little is known about the clinical implication of a short QT interval, and only anecdotal reports suggest that a short QT interval could be responsible for an even higher risk of sudden death.[6–8]

In the present study, we describe 2 unrelated families with idiopathic, constantly, and uniformly short QT interval at ECG in the absence of structural heart disease. Familial history of sudden cardiac death is associated with major (resuscitated cardiac arrest, syncope) or minor (palpitations, dizziness, atrial fibrillation) arrhythmic events and inducible ventricular fibrillation at programmed stimulation.

Methods

Family 1

Three patients (2 adults and 1 child) from the first family were referred for a history of syncope or palpitations, as well as resuscitated sudden death in one case. They had a strong family history of sudden death, which was present in 4 generations, as shown in the pedigree outlined in Figure 1A. All of them had a very short QT interval at ECG, which never exceeded 280 and 290 ms when corrected for heart rate with Bazett's formula (QTc). These patients underwent extensive evaluation, including physical examination, serial ECGs, exercise testing, 24-hour Holter monitoring, heart variability, QT dispersion, signal-averaged ECG, echocardiogram, and cardiac MRI.

Electrophysiological Study

After informed written consent was obtained, a detailed electrophysiological study was performed in the 2 adult patients. Ventricular programmed stimulation was performed at 2 ventricular sites (right

Received March 17, 2003; revision received June 2, 2003; accepted June 3, 2003.

From the Division of Cardiology (F.G., C.G., F.B., R.R., S.G., E.R.), Ospedale Mauriziano Umberto I, Torino, Italy; and the 1st Department of Medicine (C.W., R.S., M.B.), University Hospital Mannheim, University of Heidelberg, Mannheim, Germany.

Correspondence to Fiorenzo Gaita, MD, Division of Cardiology, Ospedale Mauriziano Umberto I, Largo Turati, 62, 10126 Torino, Italy. E-mail gaitaf@libero.it

© 2003 American Heart Association, Inc.

Circulation **is available at http://www.circulationaha.org** **DOI: 10.1161/01.CIR.0000085071.28695.C4**

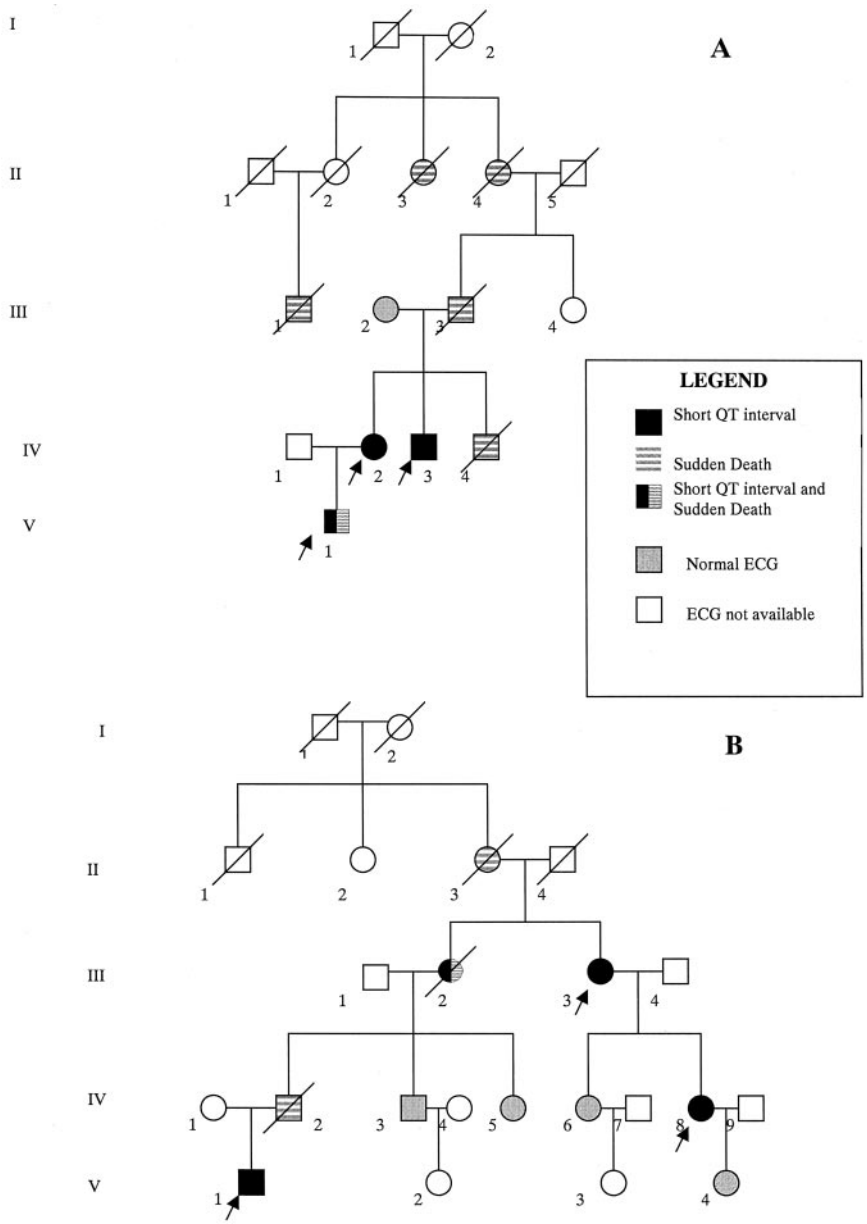

Figure 1. Pedigree of the affected families. A, Pedigree of family 1. B, Pedigree of family 2. Circles indicate female family members; squares, male family members; symbols with a slash, deceased family members; solid symbols, patients with documented short QT; striped symbols, family members who suffered from sudden death; open symbols, subjects with ECG not available; gray symbols, subjects with documented normal ECGs; and arrows, subjects who were submitted to clinical and instrumental evaluation.

Downloaded from http://circ.ahajournals.org/ by guest on March 22, 2017

ventricular apex and outflow tract) at 2 different pacing cycle lengths, with 1 and 2 extrastimuli to the refractory period.

Electrophysiological study was repeated after flecainide administration (2 mg/kg IV over 10 minutes). Flecainide was administered to rule out Brugada syndrome. Because this drug prolongs effective refractory periods (ERPs) acting on sodium channels, we intended to verify if this would occur in our patients, and if this were the case, if it could prevent induction of arrhythmias.

Family 2

Two patients from a second family were referred for syncope, palpitations, and a strong family history of sudden death, which was present in 3 generations, as shown in the pedigree in Figure 1B. Three of the family members presented a short QT interval at ECG, which never exceeded 270 and 300 ms when corrected for heart rate with Bazett's formula (QTc). These patients underwent extensive clinical and instrumental evaluation, including physical examination, serial ECGs, 24-hour Holter monitoring, echocardiogram, exercise testing, and cardiac MRI.

Electrophysiological Study

After informed written consent was obtained, patients were submitted to electrophysiological study with ventricular programmed stimulation from 2 ventricular sites (right ventricular apex and outflow tract) at 3 different pacing cycle lengths with up to 3 extrastimuli to the refractory period. Programmed stimulation was repeated after flecainide administration (2 mg/kg IV in 10 minutes).

Results

Family 1

Patient 1 (IV, 3; Figure 1A) is a 35-year-old white man who had a history of syncope during exertion and paroxysmal atrial fibrillation. Some ECGs and one Holter recording showed frequent isolated monomorphic ventricular extrasystoles with right bundle branch and left-axis deviation morphology, suggesting a left posterior fascicular origin.

All available ECGs performed in his life showed left-axis deviation, a QT interval ranging from 240 to 280 ms, and QTc

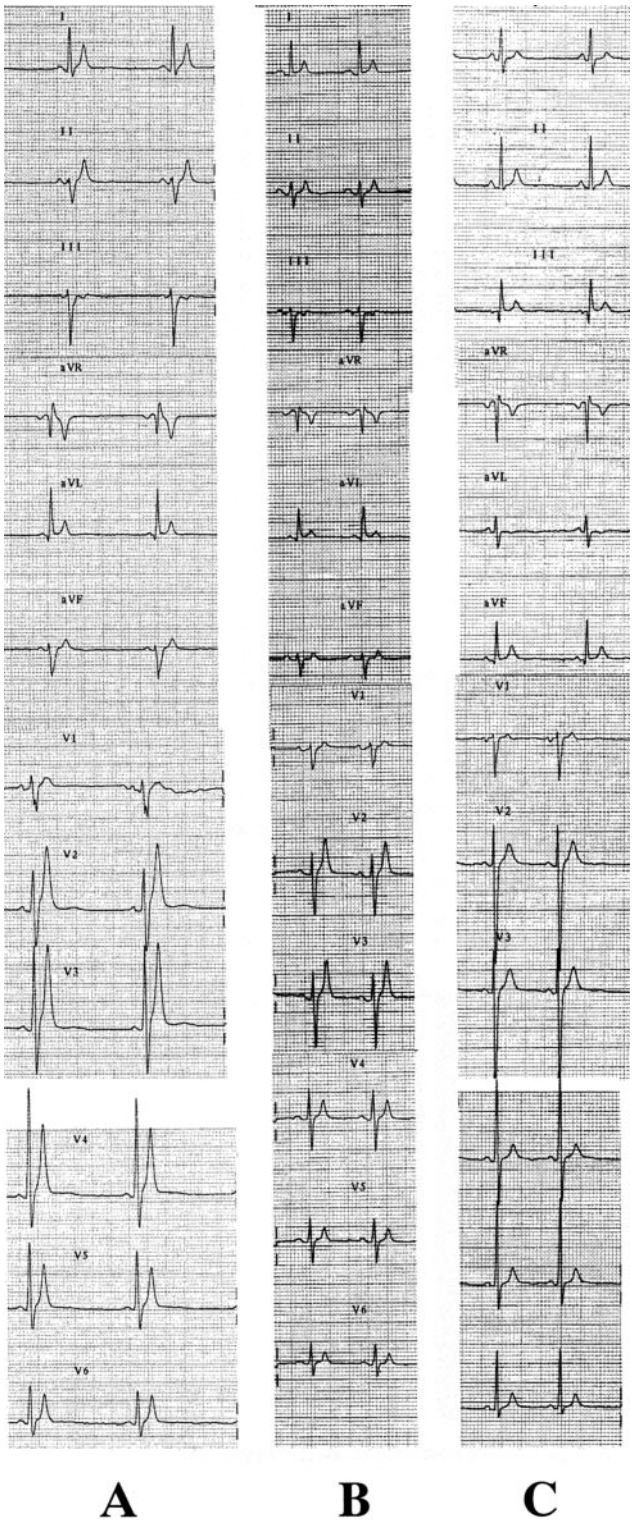

Figure 2. Twelve-lead ECG (25 mm/s paper speed) of family 1 patients. A, Patient 1 (IV, 3): sinus rhythm, heart rate 52 beats per minute (bpm); left-axis deviation, QT 280 ms. B, Patient 2 (IV, 2): sinus rhythm, heart rate 96 bpm; left-axis deviation, QT 220 ms. C, Patient 3 (V, 1): sinus rhythm with mean heart rate 92 bpm, QT 260 ms.

never exceeding 280 ms (Figure 2A). Since the first episode of atrial fibrillation at the age of 18 years, several ECGs had been recorded during his life, both in sinus rhythm and in atrial fibrillation.

Patient 2 (IV, 2; Figure 1A), the sister of patient 1, is a 31-year-old woman who had a similar ECG pattern with left-axis deviation and QT interval between 220 and 250 ms (QTc ≤290 ms), as shown in Figure 2B. She was symptomatic for dizziness and palpitations. In this patient as well, several ECGs and one Holter recording showed isolated and monomorphic ventricular extrasystoles with right bundle-branch block, left-axis deviation morphology, and variable coupling.

During stress testing in both patients, a slight reduction of the QT occurred (from 280 to 240 ms in patient 1 and from 240 to 230 ms in patient 2) during physiological increase in heart rate.

Patients did not complain of any symptoms during exercise.

Patient 3 (V, 1; Figure 1A), the 6-year-old son of patient 2, had a cardiac arrest at the age of 8 months after an adrenergic stress (a loud noise). He was successfully resuscitated with DC shock but had severe neurological damage because of prolonged cerebral hypoxia. This child showed the same ECG pattern (Figure 2C) with short QT interval (ranging from 240 ms to 260 ms, QTc ≤290 ms), as observed in his mother and uncle.

No evidence of structural heart disease was found in any of these patients during extensive noninvasive and invasive evaluation (echocardiogram, cardiac MRI, stress test). Signal-averaged ECG, heart variability, and QT dispersion were all in the normal range.

Family History

Patients 1 and 2 had another brother who died suddenly at the age of 3 months (IV, 4; Figure 1A). The father of the siblings (III, 3; Figure 1A) died suddenly at the age of 39 years. He was symptomatic for dizziness. Structural heart disease could be ruled out by autopsy. Three other family members died suddenly as shown in Figure 1A. The paternal grandmother (II, 4; Figure 1A) of the siblings died suddenly at the age of 49 years; she was not suffering from any disease. The grandmother had 2 sisters, one of which (II, 3; Figure 1A) died suddenly. The other sister had a son (III, 1; Figure 1A) who died suddenly at the age of 39 years. ECG recordings could not be obtained from these patients. The mother (III, 2; Figure 1A) of the siblings had a normal ECG and no family history of heart disease or sudden death.

Electrophysiological Study

Electrophysiological study was performed in patients 1 and 2. Catheter positioning in the right ventricle induced ventricular fibrillation in both.

In both patients, ventricular ERP did not exceed 150 ms at any pacing site or pacing cycle length (range, 140 to 150 ms in patient 1 and 130 to 140 ms in patient 2). Ventricular fibrillation was induced in both by programmed ventricular stimulation using 2 premature extrastimuli at the right ventricle outflow tract of the right ventricle (Figure 3). During atrial programmed stimulation, atrial fibrillation was induced in the patient with history of spontaneous atrial arrhythmias. In the other patient, atrial ERP was 120 ms; atrial fibrillation was not induced.

Downloaded from http://circ.ahajournals.org/ by guest on March 22, 2017

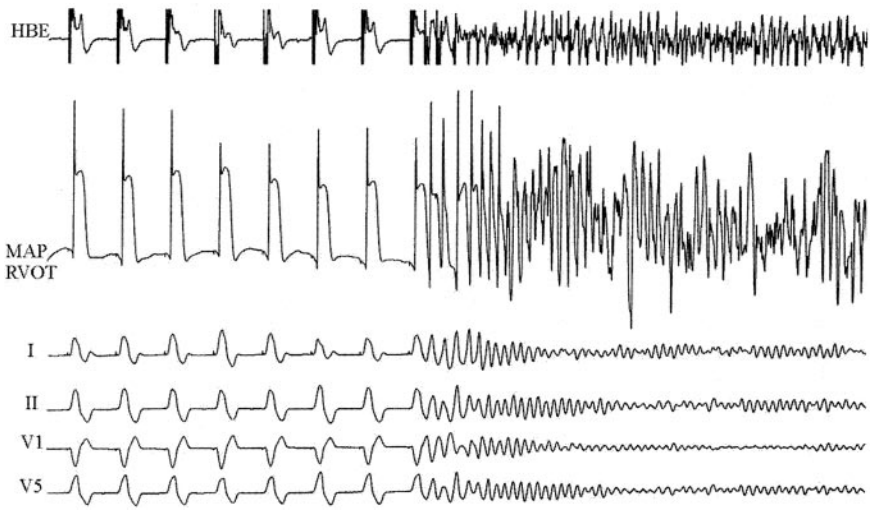

Figure 3. Ventricular fibrillation induced by programmed stimulation from right ventricle outflow tract. Pacing cycle length, 550 ms, S_1S_2 170 ms, S_2S_3 150 ms. Paper speed, 25 mm/s. HBE indicates recording from His Bundle region; MAP RVOT, monophasic action potential recording from right ventricle outflow tract. I, II, V1, and V5 indicate surface ECG leads.

After intravenous flecainide, ventricular programmed stimulation showed in both patients a prolongation of the ERPs (to 170 ms in patient 1 and to 240 ms in patient 2 at a pacing cycle length of 550 ms), and ventricular arrhythmias were no longer inducible. Monophasic action potential duration measured at the level of 90% repolarization (MAP_{90}) was 160 ms in both patients at a pacing cycle length of 550 ms and 150 and 135 ms, respectively, in patients 1 and 2 at a pacing cycle length of 400 ms. After flecainide, MAP_{90} was 170 ms at a pacing cycle length of 550 ms in patient 1 and 180 ms in patient 2.

An automatic defibrillator (ICD) was implanted in both patients.

Family 2

Patient 4 (III, 3; Figure 1B) is a 67-year-old woman symptomatic for palpitations, who had frequent ventricular and supraventricular extrasystoles and one episode of paroxysmal atrial fibrillation. Her ECG was characterized by a QT interval of 270 ms (QTc 295 ms), as shown in Figure 4A.

Patient 5 (V, 1; Figure 1B) is the 15-year-old nephew of patient 4 and is symptomatic for syncope. He had a QT interval of 260 ms (QTc 300 ms), as shown in Figure 4B.

Patient 6 (IV, 8; Figure 1B) is the 40-year-old daughter of patient 4. She had a QT interval of 240 ms (QTc 268 ms) at ECG (Figure 4C) and is asymptomatic.

Structural heart disease was ruled out in all patients.

Family History

The mother (II, 3; Figure 1B) of patient 4 died suddenly at the age of 45 years, as witnessed by patient 4. In the last days, she had suffered from pain in the right leg, which was red and swollen; she did not complain of dyspnea. She was found in the morning lying dead in bed. No ECG recording was

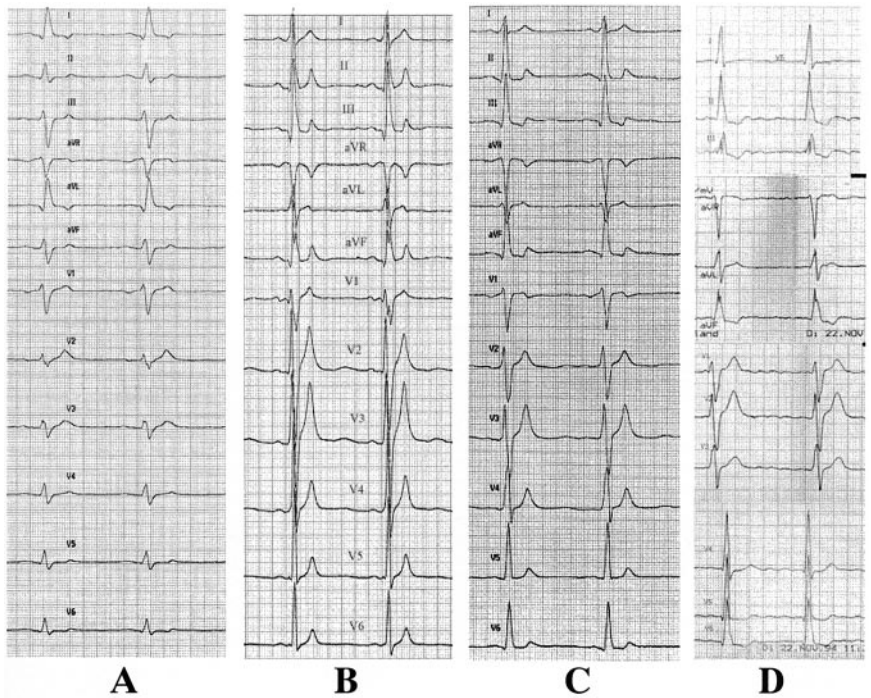

Figure 4. Twelve-lead ECG (50 mm/s paper speed) of family 2 patients. A, Patient 4 (III, 3): sinus rhythm, heart rate 72 bpm; QT 270 ms. B, Patient 5 (V, 1): sinus rhythm, heart rate 80 bpm; QT 260 ms. C, Patient 6 (IV, 8): sinus rhythm, heart rate 75 bpm; QT 240 ms. D, ECG of the patient III, 2, who died suddenly: atrial fibrillation, QT interval 210 ms at a mean heart rate of 85 bpm.

Downloaded from http://circ.ahajournals.org/ by guest on March 22, 2017

available. Her husband (II, 4; Figure 1B), father of patient 4, died during the second World War. The woman had a brother (II, 1; Figure 1B) who also died during the second World War and a sister (II, 2; Figure 1B) who is alive and has a normal ECG.

The sister (III, 2; Figure 1B) of patient 4 died suddenly at the age of 62 years. She was suffering from atrial fibrillation and had a QT interval at ECG of 210 ms (QTc 250 ms), as shown in Figure 4D. Her son (IV, 2), father of patient 5, had at the age of 26 years a syncope after exertion, witnessed by his wife; he regained consciousness, then again collapsed with loss of consciousness. Cardiopulmonary resuscitation was performed without success by the general practitioner, who documented ventricular fibrillation. At autopsy, no evidence of organic heart disease was found. No previous ECG was available; however, both his mother and son had a short QT interval at ECG.

The other sons (IV, 3 and IV, 5; Figure 1B) and the nephew (V, 2) are asymptomatic; they present a normal QT interval at ECG.

The daughter (IV, 6; Figure 1B) of patient 4, sister of patient 6, is asymptomatic and has a normal ECG with normal QT interval; her child (V, 3; Figure 1B) is asymptomatic, with normal QT interval at ECG. The daughter (V, 4; Figure 1B) of patient 6 is asymptomatic and has a normal ECG pattern with normal QT interval.

Electrophysiological Study

In Patient 4 (III, 3; Figure 1B), ventricular ERPs were very short at all pacing sites and pacing cycle lengths (140 to 150 ms). A very fast monomorphic ventricular tachycardia (with cycle length of 150 ms) was induced by programmed ventricular stimulation with 3 extrastimuli at the right ventricular outflow tract. Atrial ERP was 140 ms at a basal cycle length of 600 ms. An ICD was implanted; at predischarge test, programmed stimulation from the right ventricular apex induced monomorphic ventricular tachycardia with a cycle length of 160 ms. After intravenous flecainide, ERP increased to 190 ms; ventricular fibrillation could still be induced.

In Patient 5 (V, 1; Figure 1B), ventricular ERP was 140 ms at any pacing site and at different pacing cycle lengths. Programmed stimulation did not induce sustained ventricular tachyarrhythmias. Atrial ERP was 160 ms at a basal cycle length of 600 ms. In consideration of the history of syncope and of the strong family history of sudden death, in the presence of short QT, an ICD was implanted prophylactically.

Discussion

In recent years, several syndromes potentially responsible for arrhythmic sudden death have been described. Most of them have been primarily identified from abnormal baseline ECG patterns in patients with aborted sudden cardiac death and their relatives. The suggested mode of inheritance has predominantly been autosomal dominant.[2–4,9–11] The first clinical entity with the combination of an ECG abnormality in the absence of structural heart disease with an increased risk for sudden death was the congenital long QT syndrome (LQTS).[1–3] Soon after the first description of the LQTS, the presence of a genetic substrate encoding defective ion channel proteins could be confirmed with the development of DNA mapping techniques.[10–12] However, even today, only up to 60% to 70% of patients with LQTS have a genetic defect confirmed at extensive screening.

Although the correlation between long QT interval and sudden death is established today, very little is known about the electrophysiological and prognostic meaning of a short QT interval. In one population study, Algra et al[8] measured QT from 6693 consecutive Holter recordings and observed that an increased risk of dying suddenly was present not only in patients with long QT, but also in patients with short QT (<400 ms). However, the study design did not permit further clinical conclusions.

In the 2 families described in the present study, several subjects showed an ECG pattern characterized by a short QT interval, below the normal limits for QT interval reported in population studies.[13–15] This alteration of the repolarization period could be documented in all available ECGs recorded at different time points and ages, with a QT interval always <300 ms, without significant dynamic changes during heart rate variations or on exertion. QT interval constantly ≤300 was regarded as short QT.

Family members presented with a wide spectrum of clinical manifestations, ranging from mild symptoms such as palpitations and dizziness to syncope and sudden death. Sudden death in the presence of short QT interval occurred in several generations, in both male and female subjects, which suggests an autosomal dominant mode of inheritance. Noteworthy, 2 sudden deaths (1 resuscitated) occurred in children in their first year of life. Noninvasive and invasive evaluation revealed structurally normal hearts, and autopsies were not indicative for cardiac disease.

To understand how a short QT interval may be related to life-threatening arrhythmias, we have to consider that QT interval is the electrocardiographic expression of ventricular repolarization, and there is a constant relationship between the ventricular ERP and the QT interval.[16] Electrophysiological study confirmed that atrial and ventricular ERPs in these patients were significantly shorter than the lower border of the normal range.[17,18] The duration of the refractory periods of the myocardium is widely recognized to be an important parameter for the vulnerability of the heart to fibrillation at both atrial and ventricular levels.

Only a few reports of persistently short QT interval have been published. The ECG phenomenon of short QT interval has been previously reported by Gussak et al[6,7] in 3 members of one family, with one of them having episodes of atrial fibrillation; none of these patients had electrophysiological study performed. Furthermore, they reported that an unrelated patient with short QT interval and history of syncope died suddenly before further investigations could be performed.

Factors that shorten QT interval include increase in heart rate (which is linearly related to ventricular ERP and QT interval[16]), hyperthermia, increased calcium or potassium plasma levels, acidosis, or alterations of the autonomic tone. Because secondary causes of transient QT interval reduction were excluded in our patients, it is likely that the alteration responsible for the short QT and for the arrhythmic events is

Downloaded from http://circ.ahajournals.org/ by guest on March 22, 2017

an intrinsic factor related to the function of the membrane ion channels. Ventricular repolarization is determined by the properties and the equilibrium of the inward Na^+ and Ca^{2+} currents and of the outward K^+ currents. Ion channel protein mutations could be involved, as in other syndromes in which an alteration of the repolarization period predisposes to life-threatening arrhythmic events, such as congenital long QT syndrome and Brugada syndrome.[2,9-11]

The molecular substrate of short QT interval and related arrhythmic events should be either a factor that reduces sodium or calcium inward currents or a factor that increases potassium outward currents. The delayed rectifier potassium currents (I_k) consist of 2 components, which are I_{ks} (slowly activating potassium current) and I_{kr} (rapidly activating rectifier potassium current). In the heart, reduced I_k function leads to prolongation of the cardiac action potential and lengthening of the QT interval. In contrast, an increased activity of I_k could play a role in producing a short QT interval. As it has occurred for other syndromes in the past, it is desirable that DNA mapping techniques identify the genetic substrate in the near future. Unfortunately, at present, there are genetic syndromes in which DNA mapping techniques are able to identify the underlying genotype only in a minority of cases.[19] While awaiting molecular substrate identification, it is important that clinicians recognize this ECG pattern and its potential involvement in life-threatening arrhythmic events. So far, the disease could have been underestimated because no reports have related short QT interval to malignant arrhythmias, and sudden death may be the first clinical manifestation in otherwise healthy subjects, thus preventing ECG observation. Therefore, a short QT interval constitutes another primary electrical abnormality responsible for sudden death in the young. Nevertheless, the risk of sudden death might be present throughout the life, because in our families, it occurred both in children <1 year old and in patients >60 years old.

The molecular substrate predisposing to short QT interval should be expressed both in ventricles and atria. Besides familial sudden death and ventricular arrhythmia inducibility, 2 patients, one from each family, and one of the patients who had died suddenly also had atrial fibrillation, and atrial refractory periods were short in all patients submitted to electrophysiological study. It has been reported that atrial fibrillation can occur on a familial basis, pointing to a genetic cause of the arrhythmia in some individuals.[20–22] Considering the high incidence of atrial fibrillation in these patients, it should be noted that lone atrial fibrillation, especially in young individuals, might in some cases be related to a short QT interval.

Conclusions

We described a syndrome characterized by a very short QT interval at ECG, syncope, palpitations and familial sudden death, autosomal dominant inheritance, and inducible ventricular fibrillation at electrophysiological study.

It is likely that the alteration responsible for this syndrome is an intrinsic, congenital factor, related to the altered function of membrane ion channels involved in the myocardial repolarization.

The knowledge that a short QT interval may be associated with life-threatening arrhythmias may allow identifying a subset of high-risk patients by ECG observation. Furthermore, lone atrial fibrillation, particularly in young individuals, could be related to a short QT interval.

References

1. Jervell A, Lange-Nielsen F. Congenital deaf-mutism, functional heart disease with prolongation of the QT interval and sudden death. *Am Heart J*. 1957;54:59–68.
2. Romano C, Gemme G, Pongiglione R. Aritmie cardiache rare dell'età pediatrica. *Clin Pediatr*. 1963;45:656–683.
3. Ward OC. A new familial cardiac syndrome in children. *J Iri Med Assoc*. 1964;54:103–106.
4. Brugada P, Brugada J. Right bundle branch block, persistent st segment elevation and sudden cardiac death: a distinct clinical and electrocardiographic syndrome: a multicenter report. *J Am Coll Cardiol*. 1992;20: 1391–1396.
5. Leenhardt A, Glaser E, Burguera M, et al. Short-coupled variant of torsade de pointes: a new electrocardiographic entity in the spectrum of idiopathic ventricular tachyarrhythmias. *Circulation*. 1994;89:206–215.
6. Gussak I, Brugada P, Brugada J, et al. ECG phenomenon of idiopathic and paradoxical short QT intervals. *Card Electrophysiol Rev*. 2002;6: 49–53.
7. Gussak I, Brugada P, Brugada J, et al. Idiopathic short QT interval: a new clinical syndrome? *Cardiology*. 2000;94:99–102.
8. Algra A, Tijssen JGP, Roelandt JRTC, et al. QT interval variables from 24 hour electrocardiography and the two year risk of sudden death. *Br Heart J*. 1993;70:43–48.
9. Brugada J, Brugada P, Antzelevich C, et al. Long-term follow up of individuals with the electrocardiographic pattern of right bundle-branch block and ST-segment elevation in precordial leads V1 to V3. *Circulation*. 2002;105:73–78.
10. Priori SG, Barhanin J, Hauer RN, et al. Genetic and molecular basis of cardiac arrhythmias: impact on clinical management: parts I and II. *Circulation*. 1999;99:518–528.
11. Priori SG, Barhanin J, Hauer RN, et al. Genetic and molecular basis of cardiac arrhythmias: impact on clinical management: part III *Circulation*. 1999;99:674–681.
12. Schwartz PJ, Priori SG, Spazzolini C, et al. Genotype-phenotype correlation in the long-QT syndrome: gene specific triggers for life-threatening arrhythmias. *Circulation*. 2001;103:89–95.
13. Rautaharju PM, Zhou SH, Wong S, et al. Sex differences in the evolution of the electrocardiographic QT interval with age. *Can J Cardiol*. 1992; 8:690–695.
14. Aytemir K, Maarouf N, Gallagher MM, et al. Comparison of formulae for heart rate correction of QT interval in exercise electrocardiograms. *Pacing Clin Electrophysiol*. 1999;22:1397–1401.
15. Rautaharju PM, Zhang ZM. Linearly scaled, rate-invariant normal limits for QT interval: eight decades of incorrect application of power functions. *J Cardiovasc Electrophysiol*. 2003;13:1211–1218.
16. Guss SB, Kastor JA, Josephson ME, et al. Human ventricular refractoriness: effects of cycle length, pacing site and atropine. *Circulation* 1976;53:3:450–455.
17. Morady F, Kadish AH, Toivonen LK, et al. The maximum effect of an increase in rate on human ventricular refractoriness. *Pacing Clin Electrophysiol*. 1988;11:2223–2233.
18. Akhtar M, Damato AN, Batsford WP, et al. A comparative analysis of antegrade and retrograde conduction patterns in man. *Circulation*. 1975; 52:766–778.
19. Wilde AAM, Antzelevich C, Borggrefe M, et al, for the Study Group on the Molecular Basis of Arrhythmias of the European Society of Cardiology. Proposed diagnostic criteria for the Brugada syndrome: consensus report. *Circulation*. 2002;106:2514–2519.
20. Chen YH, Xu SJ, Bedahlou S, et al. KCNQ1 gain-of-function mutation in familial atrial fibrillation. *Science*. 2003;299:251–254.
21. Brugada R, Tapscott T, Czernuszewicz GZ, et al. Identification of a genetic locus for familial atrial fibrillation. *N Engl J Med*. 1997;336: 905–911.
22. Eckardt L, Kirchoff P, Loh P, et al. Brugada syndrome and supraventricular tachyarrhythmias: a novel association? *J Cardiovasc Electrophysiol*. 2001;12:680–685.

Downloaded from http://circ.ahajournals.org/ by guest on March 22, 2017

Circulation

Short QT Syndrome: A Familial Cause of Sudden Death

Fiorenzo Gaita, Carla Giustetto, Francesca Bianchi, Christian Wolpert, Rainer Schimpf, Riccardo Riccardi, Stefano Grossi, Elena Richiardi and Martin Borggrefe

Circulation. 2003;108:965-970; originally published online August 18, 2003;
doi: 10.1161/01.CIR.0000085071.28695.C4
Circulation is published by the American Heart Association, 7272 Greenville Avenue, Dallas, TX 75231
Copyright © 2003 American Heart Association, Inc. All rights reserved.
Print ISSN: 0009-7322. Online ISSN: 1524-4539

The online version of this article, along with updated information and services, is located on the World Wide Web at:
http://circ.ahajournals.org/content/108/8/965

Downloaded from http://circ.ahajournals.org/ by guest on March 22, 2017

Permissions: Requests for permissions to reproduce figures, tables, or portions of articles originally published in *Circulation* can be obtained via RightsLink, a service of the Copyright Clearance Center, not the Editorial Office. Once the online version of the published article for which permission is being requested is located, click Request Permissions in the middle column of the Web page under Services. Further information about this process is available in the Permissions and Rights Question and Answer document.

Reprints: Information about reprints can be found online at:
http://www.lww.com/reprints

Subscriptions: Information about subscribing to *Circulation* is online at:
http://circ.ahajournals.org//subscriptions/